

Myocardial Characterization

## An Interleaved T1–T2\* Imaging Sequence for Assessing Myocardial Injury

---

Ganghong Tian,<sup>1</sup> Jie F. Shen,<sup>2</sup> Guangping Dai,<sup>1</sup>  
Jiankang Sun,<sup>1</sup> Bo Xiang,<sup>1</sup> Zhezong Luo,<sup>1</sup> Ray Somorjai,<sup>1</sup>  
and Roxanne Deslauriers<sup>1</sup>

<sup>1</sup>Institute for Biodiagnostics, National Research Council Canada, Winnipeg,  
Manitoba, Canada

<sup>2</sup>GE Medical Systems, Milwaukee, Wisconsin

### ABSTRACT

*We developed a sequence by which T1- and T2\*-weighted images can be acquired simultaneously and demonstrated its validity for assessing myocardial injury. The interleaved T1–T2\* imaging sequence consisted of one preparatory pulse (a 90° pulse) and a gradient-echo imaging sequence with a dynamically variable echo time varying between 4.2 msec for T1-weighted imaging and 15 msec for T2\*-weighted imaging. The sequence was tested and validated on isolated blood-perfused pig hearts (n = 4). We found that contrast agent-induced T1 and T2\* effects were clearly delineated during the first-pass and steady-state periods of a contrast agent (gadolinium diethylenetriaminopentaacetic acid). With a bolus injection of contrast agent, the maximum changes in T2\* signal intensity occur significantly earlier than the changes in T1 signal. We also found that the maximum change in T1 signal intensity during the first pass of contrast agent was significantly greater in a reperfused-infarcted region than in normal regions. The suppression of T2\* signal was similar in both regions. At steady state of contrast agent, T2\* signal intensities gradually recovered to a significantly higher level in the reperfused-infarcted region than in normal regions. This suggests that the contrast agent diffused into the intracellular space, indicating the loss of cell membrane integrity. As a result, T1 signal intensity was also higher in the reperfused-infarcted myocardium than in normal myocardium. T1- and T2\*-weighted images can be acquired simultaneously. The interleaved T1–T2\* sequence is useful in assessing myocardial injury.*

**KEY WORDS:** Contrast agent; MR imaging; Myocardial infarction; Myocardial perfusion; Pig heart; T1–T2\* imaging.

Received August 6, 1998; Accepted October 21, 1998

Address reprint requests to G. Tian.

## INTRODUCTION

The assessment of myocardial injury has been greatly improved by the use of magnetic resonance (MR) imaging and spectroscopy (1,2). It has been suggested that myocardial injury can be assessed in several ways, including myocardial blood perfusion, tissue magnetic characteristics (T1 and T2 relaxation times), the distribution of contrast agents, myocardial energy metabolism, and contractile function (3–7). With respect to MR perfusion imaging, the T1-weighted technique has been more frequently used for assessing myocardial viability than the T2\* method because of its high magnitude of enhancement effect (7). T2\*-weighted imaging has been thought to suffer major limitations, including its sensitivity to the distortion in the local magnetic field and susceptibility artifacts (7,8). We showed in a previous study that T1- and T2\*-weighted imaging convey different information regarding tissue perfusion (9,10). The T2\*-weighted method appears to be more sensitive to capillary flush-in, whereas the T1-weighted method seems more sensitive to diffusion processes (9,10). Therefore, it is our hypothesis that the combination of these two sequences may help assess myocardial viability and tissue blood flow.

It has been generally accepted that the loss of cell membrane integrity is one of the important markers of irreversible myocardial injury (11,12). Any technique that can detect the destruction of the cell membrane is expected to be useful in assessing myocardial viability. The efficacy of T1-weighted imaging in conjunction with extracellular contrast agents has been under extensive investigation for assessing myocardial injury. The loss of cell membrane integrity that results from myocardial infarction may increase the distribution volume for contrast agents, and thus the concentration of contrast agents is expected to be higher in damaged tissue than in normal tissue. This leads to a shorter T1 relaxation times and higher T1 signal intensity in damaged areas than in normal areas of the myocardium.

In addition, the increase of contrast distribution volume may improve the homogeneity of local magnetic field, which will decrease the T2\* effect and increase the signal intensity of T2\*-weighted images. Therefore, it was expected that T2\* images would show higher intensity in infarcted regions than in normal regions. Because of the different changes in T2\* signal intensity, we believe that T2\*-weighted imaging is also sensitive to the loss of cell membrane integrity.

For first-pass perfusion imaging, two injections of contrast agents are required if both T1- and T2\*-weighted

imaging are to be performed. This may be inconvenient in clinical situations. Therefore, if the two imaging sequences were combined, the time course of both T1- and T2\*-weighted images could be obtained with a single injection of contrast agent. The temporal relation between the changes in T1 and T2\* signal intensities can be delineated, which may also help assess myocardial injury and tissue blood flow.

The purpose of this study was to establish an interleaved T1–T2\* sequence by which T1- and T2\*-weighted images were acquired simultaneously. We also evaluated this sequence in pig hearts subjected to a 3-hr occlusion of the anterior descending coronary artery (LAD) and 1-hr reperfusion. The results of this study suggest that the interleaved T1–T2\* imaging sequence provides a useful approach for the assessment of myocardial viability.

## MATERIALS AND METHODS

### Isolated Heart Preparation

All animals received humane care in compliance with the Canadian Council on Animal Care's guide to the care and use of experimental animals. The protocols of this study were approved by the National Research Council Animal Care Committee.

Domestic pigs weighing 45–50 kg were sedated with an intramuscular injection of midazolam (0.4 mg/kg body wt) and ketamine (20 mg/kg body wt). Anesthesia was maintained with 1–2% isoflurane in a mixture of oxygen and nitrous oxide. The respiratory rate and volume were adjusted to keep the arterial blood gases within the normal physiologic range. The brachiocephalic artery was cannulated at the level of the common carotid artery for arterial pressure monitoring, blood sampling, and the infusion of cardioplegic solution. A sternotomy was performed, and the pericardium was opened longitudinally along the midline. Anticoagulation was provided by the injection of heparin (3000 IU) into the superior vena cava. Heparinized cold (4°C) cardioplegic solution was infused into the aortic root (10 ml/kg body wt) to arrest the heart. The heart was then excised. The brachiocephalic artery was joined to a cannula to be connected to a Langendorff perfusion apparatus. The heart was then placed in an MR unit and perfused in the Langendorff apparatus with a mixture of pig blood and Krebs-Henseleit (K-H) solution with various concentrations of potassium (4.7 or 16 mmol/l) according to the protocol.

## MR Imaging

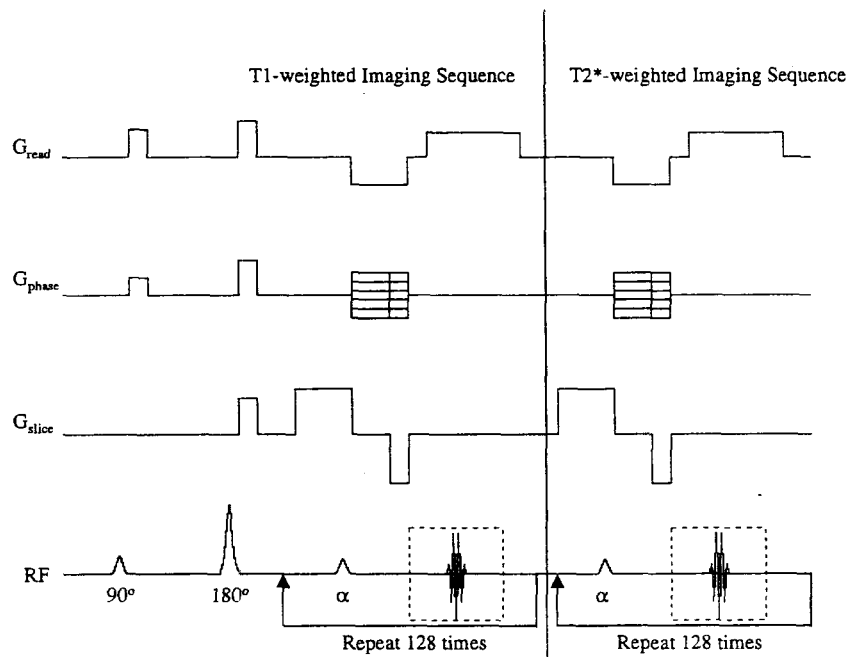
MR perfusion imaging was performed on a 7-T 40-cm system (Bruker Inc., Karlsruhe, Germany). The isolated hearts were suspended vertically inside a double-turn 10-cm-diameter Helmholtz coil. The interleaved T1-T2\* imaging sequence is illustrated in Fig. 1. The sequence consisted of one preparatory pulse ( $90^\circ$ ) and a gradient-echo sequence with a dynamically variable echo time. The echo time (TE) varied from 4 msec for T1-weighted imaging to 15 msec for T2\*-weighted imaging. The repetition times (TR) for T1- and T2\*-weighted imaging were 6.75 and 18.15 msec, respectively. The inversion pulse was active only during the acquisition of T1-weighted images. The purpose of the initial  $90^\circ$  pulse was to eliminate interference between T2\* imaging and subsequent T1 imaging. Images were acquired from a 4-mm-thick slice with a  $12\text{-cm}^2$  field of view and image matrix size of  $128 \times 128$ , resulting in an in-plane resolution of  $0.87\text{ mm}^2$ . The acquisition times for T1- and T2\*-weighted images were 894 and 2324 msec, respectively. The images were acquired along the short cardiac axis. This orienta-

tion of the images provides the best view of myocardial perfusion throughout the heart with a single slice. Two hundred images were acquired with each injection of contrast agents. In the present study, all MR images were acquired from arrested pig hearts to eliminate any potential motion influence.

## Experimental Design

Four isolated pig hearts were used to determine whether both T1 and T2\* effects could be delineated by using this interleaved T1-T2\* sequence. In this part of the study, the pig hearts were kept arrested throughout the protocol, which was achieved by perfusing the hearts with the hyperkalemic (16 mmol/l KCl and  $\text{MgCl}_2$ ) mixture of pig blood and K-H solution under a perfusion pressure of 40–50 mm Hg. K-H solution contained the following (in mmol/l): NaCl 118, KCl 4.7,  $\text{MgSO}_4$  1.2, glucose 11,  $\text{NaHCO}_3$  25,  $\text{CaCl}_2$  1.75, EDTA 0.5, and bovine serum albumin 0.5%.

Gadolinium diethylenetriaminopentaacetic acid (Gd-DTPA; 0.06 mmol/kg body wt) and Gd-DTPA-poly-



**Figure 1.** Interleaved T1- and T2\*-weighted imaging sequence. Segments in the rectangular boxes are repeated for the number of phase-encoding steps. The  $90^\circ$  pulse before the  $180^\circ$  pulse eliminates the potential interference of T2\* imaging on subsequent T1 imaging. Two spoiling gradients are placed along the directions of read-out and phase encoding.

sine (0.03 mmol/kg body wt) were injected as boluses into the perfusion line. The solutions containing the contrast agents were not recirculated to eliminate any influence of an injection on a subsequent one. The two injections of the contrast agents were separated with a minimum 5-min time gap to ensure complete washout of the contrast agent injected previously. Eight T1-weighted images were acquired before the second injection of contrast agent to determine if any contrast agent remained in myocardium.

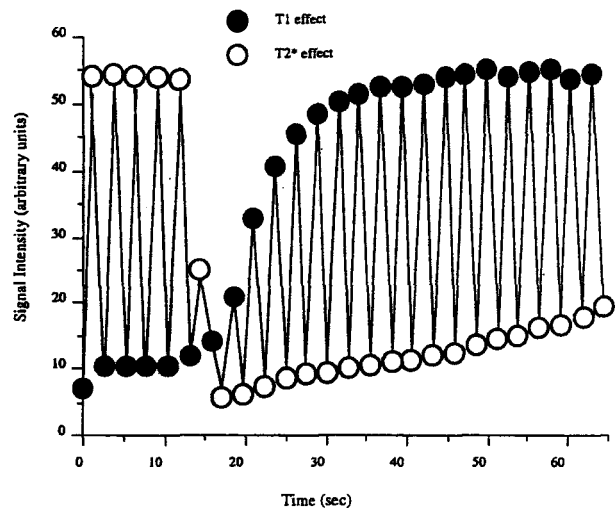
To determine the efficacy of the interleaved T1–T2\* sequence in the assessment of myocardial injury, regional myocardial infarction was induced in four isolated beating hearts by a 3-hr occlusion of the LAD and 1-hr reperfusion (release of the occlusion). After reperfusion, the hearts were maintained in arrest for MR imaging. Gd-DTPA (0.03 mmol/kg body wt) was injected into the perfusion line. Two hundred images were acquired continuously using the interleaved T1–T2\* sequence to capture the changes in T1 and T2\* effects during the first pass and at steady state of the contrast agent. After imaging, the hearts were cut into 1.0-cm-thick slices parallel in plane to the short cardiac axis. The slices were then incubated in a 1% triphenyl tetrazolium chloride (TTC) solution to delineate infarcted myocardium. MR perfusion images were then analyzed based on the TTC-stained pictures.

### Image Processing and Data Analysis

Images were analyzed using EvIdent (a two- and three-dimensional image analysis software, Institute for Biodiagnostics, NRC, Winnipeg, Canada). The regions of interest were defined by the operator using the TTC-stained pictures as references. The signal-intensity curves over time were generated from the reperfused-infarcted area and the normal area of the myocardium. Signal intensity measurements for the normal area of the myocardium were obtained from the posterior wall of the left ventricle. The maximum changes in signal intensities between the two areas were compared using Student's *t*-test (STATISTICA, STATSOFT Inc., Tulsa, OK). Data are expressed as the mean  $\pm$  SD.

## RESULTS

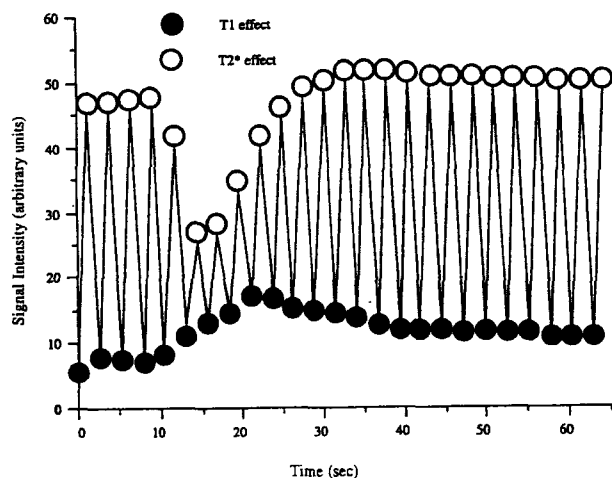
A representative time course of the signal intensities of T1- and T2\*-weighted images obtained using the interleaved T1–T2\* sequence and Gd-DTPA is shown in Fig.



**Figure 2.** Representative time courses of T1- and T2\*-weighted images obtained using the interleaved signal intensities, and open circles illustrate the effect on T2\* signal intensities. The injection of contrast agents resulted in rapid suppression in T2\* signal intensity and a gradual increase in T1 signal intensity.

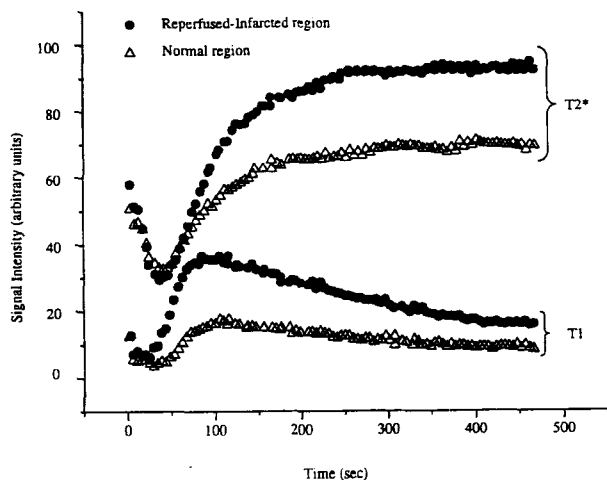
2. The arrival of the contrast agent resulted in a rapid decrease in T2\* signal intensity and a gradual increase of T1 signal intensity. The maximum effect on T2\* occurred when the changes in T1 signal were only approximately 10% of their maximum. The temporal relation between the T1 and T2\* effects was similar to that observed in our previous study in which separate T1-weighted and T2\*-weighted sequences were used under similar coronary flow conditions (9). Figure 3 shows a representative time course of the signal intensities of T1- and T2\*-weighted images obtained using the interleaved T1–T2\* sequence with an intravascular contrast agent (Gd-DTPA-polylysine). The contrast agent resulted in a large and rapid decrease of T2\* signal intensity, but its effect on T1 signal intensity was considerably smaller relative to that observed with Gd-DTPA.

Representative time courses of the signal intensities of T1- and T2\*-weighted images obtained using Gd-DTPA after a 3-hr LAD occlusion are shown in Fig. 4. Gd-DTPA caused a similar decrease in T2\* signal intensity in normal and infarcted myocardium, which may suggest similar blood flow in both regions. However, the maximum T1 effect was significantly greater in the infarcted region than in the normal region, suggesting that more contrast agent diffused into the interstitial and intracellular spaces in infarcted than in normal regions of the myo-



**Figure 3.** Representative time courses of T1- and T2\*-weighted images obtained using the interleaved T1-T2\* sequence and an intravascular contrast agent (Gd-DTPA-polylysine). Solid circles show the effect on T1 signal intensities and open circles represent T2\* signal intensities.

cardium. As the contrast agent was diluted within the perfusion system, its concentration in the myocardium gradually declined. As a result, T1 signal intensity in both regions decreased gradually. At the end of the imaging experiment, the T1 and T2\* signal intensities had almost reached steady state. The T1 signal intensity was significantly higher in the reperfused-infarcted myocardium



**Figure 4.** Comparison of the time courses of T1 and T2\* signal intensities from reperfused-infarcted and normal myocardium with Gd-DTPA.

than in normal myocardium ( $34.2 \pm 12$  versus  $16.7 \pm 6.3$  arbitrary unit,  $p < 0.05$ ). This suggests a greater concentration of contrast agent in the reperfused-infarcted myocardium than in normal myocardium. Moreover, the T2\* signal intensity was also significantly higher in the reperfused-infarcted myocardium relative to that in normal myocardium ( $100 \pm 15.8$  versus  $72 \pm 11$  arbitrary unit,  $p < 0.05$ ). This suggests that the regional magnetic field was more homogeneous in the infarcted than in the normal area of the myocardium as a result of the breakdown of cell membrane integrity. This also supports the hypothesis that the greater T1 signal intensity observed in the infarcted area was due to an increase in the distribution volume of the contrast agent.

### DISCUSSION

The application of MR imaging together with contrast agents is a promising approach for the assessment of myocardial injury (13,14). Most studies have used T1-weighted imaging for assessing myocardial injury and determining myocardial blood flow (15-19). We developed an interleaved T1-T2\* sequence whereby T1- and T2\*-weighted images can be acquired simultaneously and the time courses of image intensities can be readily delineated after injection of a contrast agent. The maximum changes in T1 and T2\* signal intensities during the first pass of Gd-DTPA occur at different times, indicating that T1- and T2\*-weighted imaging are sensitive to different processes in tissue perfusion. Using this sequence, both T1 and T2\* signal intensities are significantly higher in the reperfused-infarcted myocardium than in normal myocardium.

Identification of myocardial ischemia and infarction has been greatly improved with the use of MR imaging and contrast agents. Several MR approaches for assessing myocardial injury have been evaluated experimentally and clinically. These methods include determining myocardial horizontal and longitudinal relaxation times (20-22), measuring contrast-enhanced T1 signal intensity (23), determining the up-slope of the contrast agent-induced signal increase (16), and indirectly determining the distribution volume of contrast agents (24-26). Because of its large signal-enhancement amplitude, T1-weighted imaging in combination with a paramagnetic contrast agent has been the most common technique used for assessing tissue viability. The hypothesis of this approach is that if myocytes lose their membrane integrity as a result of irreversible injury, the distribution space for contrast agents increases (25,26). The amount of contrast

agent per unit tissue volume also increases, leading to shorter T1 relaxation times and higher signal intensities of T1-weighted images. Based on the shortening of T1 relaxation times or the increase in signal intensities, the diffusion coefficient or distribution volume may be calculated (25,26). However, the T1-weighted technique is only sensitive to the amount of contrast agent in a given volume of tissue. Observed changes in T1 relaxation times or signal intensities are not directly related to the spatial distribution of contrast agent. Thus, the T1-weighted method alone may not be sufficient for determining tissue integrity, although it has played an important role in the area.

T2\*-weighted imaging is sensitive to the homogeneity of the local magnetic field (7,27). When a contrast agent is flushing into the capillaries, the inhomogeneous distribution creates local magnetic gradients at the boundaries of the capillaries. These local magnetic gradients will result in a rapid decrease in T2\* signal intensities. As the contrast agent crosses the capillary walls and diffuses into the macroscopically more homogeneous interstitial space, local magnetic gradients begin to diminish, leading to a gradual recovery of T2\* signal intensity. If cell membrane integrity is lost, the contrast agent can diffuse into the intracellular space. At this stage, all three tissue compartments are equally filled with contrast agent. Consequently, local magnetic gradients drop to the minimum levels and T2\* signal intensities may reach their highest plateau. We postulate that this is the cause of the higher T2\* signal intensities observed in this study in reperfused-infarcted myocardium relative to normal tissue (Fig. 4). The higher T2\* signal intensities observed in the reperfused-infarcted region support the hypothesis that the higher T1 signal intensity in the same area is also due to an increase in the distribution space of the contrast agent.

All MR images in the present study were acquired in arrested pig hearts. Both T1 and T2\* effects during first pass and at steady state of contrast agent were clearly delineated using the interleaved T1-T2\* sequence. The temporal resolution of this sequence may not be sufficient for the first-pass perfusion imaging of a beating heart. We are currently developing an interleaved T1-T2\* sequence using fast-imaging techniques that will be more applicable to clinical situations. Nevertheless, the validity of the concept (simultaneous acquisition of T1 and T2\* images) for delineating myocardial infarction has been demonstrated.

In summary, T1- and T2\*-weighted images can be simultaneously acquired using the interleaved T1-T2\* imaging sequence. Contrast agent-induced changes in T2\*

and T1 signal intensities differ significantly between infarcted and normal regions of myocardium. Therefore, simultaneous acquisition of both images is a useful approach for the assessment of myocardial viability.

## ACKNOWLEDGMENTS

Supported by the National Research Council of Canada and the Medical Research Council of Canada (grant 9609OP-3408-BME-CDAA-26321). We thank Mrs. Rachele Mariash, Mrs. Lori Gregorash, and Mrs. Shelley Germscheid for their excellent technical assistance. We also thank Schering, Berlex Inc., Berlin, Germany for generously providing the Gd-DTPA-polylysine used in this study.

## REFERENCES

1. Higgins CB, Saeed M and Wendland MF. MRI in ischemic heart disease: Expansion of the current capabilities with MR contrast. *Am Cardiac Imag*, 1991; 5:38-50.
2. Van der Wall EE, de Roos A, van Voorthuisen AE and Brusckhe AV. Magnetic resonance imaging: A new approach for evaluating coronary artery disease. *Am Heart J*, 1990; 21:1203-1220.
3. Van der Wall EE, Vliegen HW, de Roos A and Brusckhe AV. Magnetic resonance techniques for assessment of myocardial viability. *J Cardiovasc Pharm*, 1996; 28(Suppl 1):S37-S44.
4. Wu KC, Zerhouni EA, Judd RM, Lugo-Olivieri CH, Barouch LA, Schulman SP, Blumenthal RS and Lima JAC. Prognostic significance of microvascular obstruction by magnetic resonance imaging in patients with acute myocardial infarction. *Circulation*, 1998; 97:765-772.
5. Yabe T, Mitsunami K, Inubushi T and Kinoshita M. Quantitative measurements of cardiac phosphorus metabolites in coronary artery disease by <sup>31</sup>P magnetic resonance spectroscopy. *Circulation*, 1995; 92:15-23.
6. Lauerma K, Saeed M, Wendland MF, Derugin N, Yu KK and Higgins CB. The use of contrast-enhanced magnetic resonance imaging to define ischemic injury after reperfusion. Comparison in normal and hypertrophied hearts. *Invest Radiol*, 1994; 29:527-535.
7. Mühler A. Assessment of myocardial perfusion using contrast-enhanced MR imaging: Current status and future developments. *MAGMA*, 1995; 3:21-33.
8. Edelman RR and Li W. Contrast-enhanced echo-planar MR imaging of myocardial perfusion: Preliminary study in humans. *Radiology*, 1994; 190:771-777.

9. Tian G, Shen J, Su S, Kozlowski P, Sun J, Xiang B, Saunders JK and Deslauriers R. Evaluation of hydroxyethyl-starch-ferrioxamine as an intravascular MR contrast agent for assessment of myocardial perfusion. *Acta Radiol*, 1997; 38(Suppl 412):85-90.
10. Su S, Shen J, Tian G, Sun J, Saunders JK and Deslauriers R. A reevaluation of T1- and T2\*-weighted imaging methods for myocardial perfusion. Proceedings of the International Society for Magnetic Resonance in Medicine, New York, April 27-May 3, 1996, p. 684.
11. Hearse DJ, Humphrey SM, Feüvray D and De Leiris J. A biochemical and ultrastructural study of the species variation in myocardial cell damage. *J Mol Cell Cardiol*, 1976; 8:759-778.
12. Schaper J, Mulch J, Winkler B and Schaper W. Ultrastructural, functional, and biochemical criteria for estimation of reversibility of ischemic injury: a study on the effects of global ischemia on the isolated dog heart. *J Mol Cell Cardiol*, 1979; 11:521-541.
13. Geschwind JFH, Wendland MF, Saeed M, Lauerma K, Derugin N and Higgins CB. Identification of myocardial cell death in reperfused myocardial injury using dual mechanisms of contrast-enhanced magnetic resonance imaging. *Acad Radiol*, 1994; 1:310-325.
14. Kim RJ, Chen EL, Lima JAC and Judd RM. Myocardial Gd-DTPA kinetics determine MRI contrast enhancement and reflect the extent and severity of myocardial injury after acute reperfused infarction. *Circulation*, 1996; 94: 3318-3326.
15. Higgins CB, Herfkens R, Lipton MJ, Sievers R, Sheldon P, Kaufman L and Crooks LE. Nuclear magnetic resonance imaging of acute myocardial infarction in dogs: Alterations in magnetic relaxation times. *J Am Cardiol*, 1983; 52:184-188.
16. Eichenberger AC, Schuiki E, Kochli VD, Amann W, McKinnon GC and von Schulthess GK. Ischemic heart disease: Assessment of with gadolinium-enhanced ultrafast MR imaging and dipyridamole stress. *J Magn Reson Imag*, 1994; 4:425-431.
17. Lim TH, Lee DH, Kim YH, Park SW, Park PH, Seo DM, Kim ST, Lee TK and Mun CW. Occlusive and reperfused myocardial infarction: detection by using MR imaging with gadolinium polylysine enhancement. *Radiology*, 1993; 189:765-768.
18. Garcia-Dorado D, Oliveras J, Gili J, Sanz E, Peres-Villa F, Barrabes J, Carreras MJ, Salares J and Soler-Soler J. Analysis of myocardial edema by magnetic resonance imaging early after coronary artery occlusion with or without reperfusion. *Cardiovasc Res*, 1993; 27:1462-1469.
19. Wolfe CL, Moseley ME, Wikstrom MG, Sievers RE, Wendland MG, Dupon JW, Finkbeiner WE, Lipton MJ, Parmley WW and Brasch RC. Assessment of myocardial salvage after ischemia and reperfusion using magnetic resonance imaging and spectroscopy. *Circulation*, 1989; 80:969-982.
20. Williams ES, Kaplan JI, Thatcher F, Zimmerman G and Knoebel SB. Prolongation of proton spin lattice relaxation times in regionally ischemic tissue from dog hearts. *J Nucl Med*, 1980; 21:449-453.
21. Krauss XH, van der Wall EE, van der Laarse A, Doornbos J, Matheijssen NAA, de Roos A, Blokland JA, van Voorthuisen AE and Brusckhe AVG. Magnetic resonance imaging of myocardial infarction: Correlation with enzymatic angiographic and radionuclide findings. *Am Heart J*, 1991; 122:1274-1283.
22. Krauss XH, van der Wall EE, van der Laarse A, Doornbos J, de Roos A, Matheijssen NAA, van Dijkman PRM, van Voorthuisen AE and Brusckhe AVG. Follow-up of regional myocardial T2 relaxation times in patients with myocardial infarction evaluated with magnetic resonance imaging. *Eur J Radiol*, 1990; 11:110-119.
23. Revel D, Canet E, Sebbag L, Forrat R, Arteaga C, Zhao S, Lorget ME and Amiel M. First-pass and delayed magnetic resonance imaging studies of reperfused myocardial infarction with iron oxide particles. *Acad Radiol*, 1996; 3:S398-S401.
24. Pereira RS, Prato FS, Wisenberg G and Sykes J. The determination of myocardial viability using Gd-DTPA in a canine model of acute myocardial ischemia and reperfusion. *Magn Reson Med*, 1996; 36:684-693.
25. Wendland MF, Saeed M, Geschwind JF, Mann JS, Brasch RC and Higgins CB. Distribution of intracellular, extracellular, and intravascular contrast media for magnetic resonance imaging in hearts subjected to reperfused myocardial infarction. *Acad Radiol*, 1996; 3:S402-S404.
26. Wendland MF, Saeed M, Lauerma K, Derugin N, Mintorovitch J, Cavagna FM and Higgins CB. Alterations in T1 of normal and reperfused infarcted myocardium after Gd-BOPTA versus Gd-DTPA on inversion recovery EPI. *Magn Reson Med*, 1997; 37:448-456.
27. Keenan RR, Zhong J and Gore JC. Intravascular susceptibility contrast mechanisms in tissue. *Magn Reson Med*, 1994; 31:9-21.