

## Is Imaging at Intermediate Doses Necessary During Dobutamine Stress Magnetic Resonance Imaging?

---

Craig A. Hamilton,<sup>1</sup> Kerry M. Link,<sup>2,3</sup> Tiffany B. Salido,<sup>1</sup> Frederick H. Epstein,<sup>4</sup> and W. Gregory Hundley<sup>2,3</sup>

<sup>1</sup>Department of Medical Engineering, Wake Forest University School of Medicine, Winston-Salem, North Carolina

<sup>2</sup>Department of Radiology, Wake Forest University School of Medicine, Winston-Salem, North Carolina

<sup>3</sup>Department of Internal Medicine (Cardiology Section), Wake Forest University School of Medicine, Winston-Salem, North Carolina

<sup>4</sup>Department of Radiology, University of Virginia School of Medicine, Charlottesville, Virginia

### ABSTRACT

*To determine if visualization of left ventricular contraction throughout the course of a pharmacologic stress test performed with magnetic resonance imaging (MRI) (rather than solely at baseline and peak stress) is necessary, we retrospectively reviewed dobutamine MRI results in 469 consecutively referred patients for diagnosis of inducible ischemia. At each stage of pharmacologic stress, six image planes of the heart were viewed and left ventricular wall motion was scored as normal, hypokinetic, akinetic, or dyskinetic. Inducible ischemia was identified in 102 patients; in 39 patients (38%), evidence of ischemia occurred before receiving high doses of dobutamine. During testing, 103 patients developed chest discomfort consistent with angina, but only 26 of the 103 patients (25%) developed new wall motion abnormalities indicative of ischemia. Continuous image acquisition and review during dobutamine MRI pharmacologic stress testing provides a mechanism to detect ischemia and avoid premature test termination during the early stages of the procedure. Compared with protocols that image only at baseline and at peak stress, con-*

Address correspondence and reprint requests to Craig A. Hamilton.

*tinuous acquisition and review may enhance the safety and improve the diagnostic accuracy of pharmacologic stress testing during dobutamine MRI.*

**Key Words:** *Contractility; Ischemia; Magnetic resonance imaging; Stress*

## INTRODUCTION

The feasibility of using fast cine magnetic resonance imaging (MRI) for evaluation of heart wall motion in the setting of pharmacologic stress testing has been recently demonstrated (1,2). There are differences in the methodologies of these studies, however, with the former (1) using image acquisition and review at baseline and peak stress and the latter (2) using image acquisition and review throughout the course of testing (at baseline, each dosage stage, and after recovery). Because ST segments on the 12-lead electrocardiogram (ECG) cannot be monitored for ischemia during MRI stress testing (3,4), this distinction is important. Continuous image acquisition and review provides a mechanism for monitoring patients for ischemia during testing, whereas image acquisition and review at only baseline and peak stress do not.

It is presently unclear whether the additional imaging at intermediate doses provides added benefit in terms of monitoring for patient safety or providing a timely diagnosis. This retrospective study was performed to determine if image acquisition and review at intermediate doses of a dobutamine MRI stress test would provide incremental information compared with imaging solely at baseline and peak stress.

## MATERIALS AND METHODS

### Study Population

The study was approved by the Institutional Review Board of our institution, and all participants gave written informed consent. The study population consisted of 469 subjects (257 men and 212 women, aged 30–88 years) referred for diagnosis of inducible ischemia during an intravenous infusion of dobutamine and/or atropine. Patients were ineligible for enrollment if they had an implantable pacemaker or defibrillator, intracranial metal, claustrophobia, or a known contraindication to receiving dobutamine (unstable angina, severe aortic stenosis, aortic dissection, or severe hypertension).

### Study Protocol

The study protocol was described previously (2,5). After obtaining a 12-lead ECG outside the magnet, pa-

tients were positioned in the magnet with monitoring equipment (ECG, O<sub>2</sub> saturation, blood pressure), cardiac coil attached, and intravenous access established. Single-slice, multiphase, gradient echo images were obtained in six views of the heart (long axis, four-chamber, two-chamber, and base, middle, and apical short axis) (6). All six views were then acquired during each stage of graded doses of intravenous dobutamine and atropine infusion (5, 10, 20, and 40 µg/kg/min of dobutamine, optionally followed by up to 1.5 mg of atropine) designed to obtain a target heart rate of 85% maximum predicted heart rate response (MPHRR) for age.

Throughout the MRI process, 18 left ventricular (LV) segments (apical, middle, and basal segments from the six views) were visually assessed for contractility using a 4-point scoring system in which 1 was normal, 2 was hypokinetic, 3 was akinetic, and 4 was dyskinetic. Myocardial segments were identified as ischemic if the score incremented during infusion or a hypokinetic segment failed to improve contractility or elicited a biphasic response (hypokinetic at rest, improved contractility at low dose infusion, and return to a hypokinetic state at peak infusion). End points for protocol termination were fall in systolic blood pressure > 40 mm Hg, significant ventricular arrhythmias, inducible ischemia, or achievement of 85% MPHRR for age. In patients who developed chest pain but had no new wall motion abnormalities, testing was continued.

### MRI Technique

Scans were performed according to previously described methods (2,5). Eight- to 14-sec breathhold scans were performed with a 1.5-T General Electric Horizon scanner (General Electric Medical Systems, Milwaukee, WI) using a fast gradient echo segmented k-space sequence. Acquisition parameters included a 12- to 14-msec repetition time, a 5-msec echo time, a 30-degree flip angle, a 256 × 128 matrix, a 32- to 48-cm field of view, prospective ECG gating, an 8-mm slice thickness, a 31.5-kHz receiver bandwidth, and 0.75 number of excitations. The k-space segmentation was adjusted throughout the procedure, as shown in Table 1, to provide adequate temporal resolution (13–65 msec) for identification of end-systole, with the end-systolic



**Table 1**

*Adjustment of Views Per Segment in k-Space Segmentation for Adequate Temporal Resolution as the Heart Rate Varies*

| Heart Rate (beats/min) | Views per Segment | Temporal Resolution (msec) | Breathhold Duration (sec) |
|------------------------|-------------------|----------------------------|---------------------------|
| <55                    | 10                | 65                         | 10                        |
| 55–65                  | 8                 | 52                         | 13–11                     |
| 65–95                  | 6                 | 39                         | 15–10                     |
| 95–125                 | 4                 | 26                         | 15–12                     |
| 125–170                | 2                 | 13                         | 23–17                     |

View sharing is used to provide one intermediate frame between acquired frames.

frame being that frame with the smallest LV cavity dimensions.

**Wall Motion Monitoring**

After acquisition and reconstruction of each view, images were automatically transferred over Ethernet to an adjacent workstation (Ultra 1, Sun Microsystems, Mountain View, CA) for observation of LV systolic function. The workstation was equipped with a 1280 × 1024 pixel gray scale monitor to avoid color distortion due to the magnetic field of the scanner. The scanner was set up to automatically initiate image transfer as each image was reconstructed. The workstation received the images using vendor-supplied image transfer software. (The *crdidbm* and *crdginx* image-transfer programs, which run on the adjacent Sun workstation, were supplied as research software by GE Medical Systems.) The stages of image re-

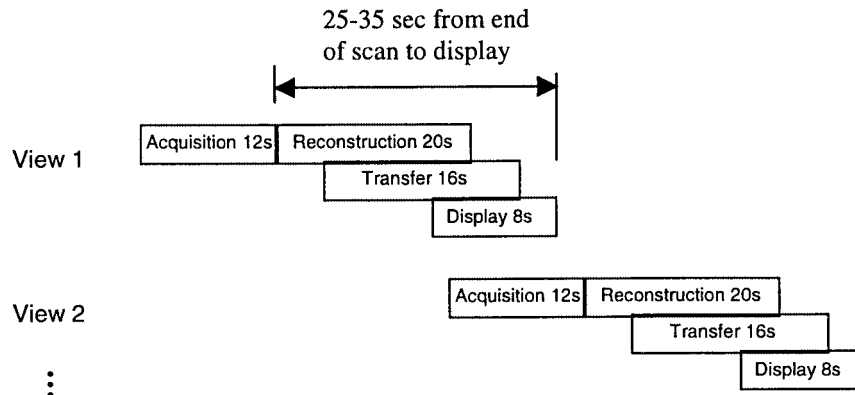
construction, transfer, and display were overlapped in time so that cine-loops of each slice could be displayed on the adjacent workstation 25 to 35 sec after image acquisition (Fig. 1).

Images were viewed on the workstation in an eight-panel format using custom display software written in IDL (Interactive Data Language, Research Systems Inc., Boulder, CO) (7). Images were cropped from 256 × 256 to 128 × 128 and then magnified by a factor of 2 before display. All cine-loops were temporally interpolated or decimated in an evenly distributed fashion to provide exactly the same number of frames in each cine-loop, thus ensuring the necessary time synchronization of all the cine-loops as the heart rate and k-space segment size varied. The viewing format was selectable so that all views of a given dose or all doses of a given view could be observed with rapid (<1 sec) switching between display formats (Figs. 2 and 3).

**RESULTS**

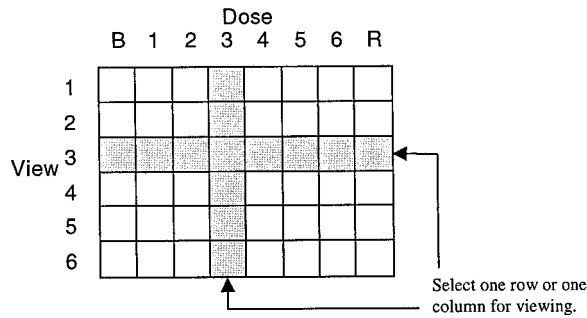
Clinical characteristics of the study population are shown in Table 2. Cine display of all LV segments was achieved in each subject throughout the examination. At peak stress, the heart rate response was 119 ± 23 beats/min and the systolic blood pressure was 147 ± 27 mm Hg. Twenty-six percent of patients received atropine to augment the heart rate response.

During the MRI procedure, verbal communication was maintained with each patient. In all subjects, visualization of segmental wall motion was achieved throughout testing. All stages of drug administration and imaging were accomplished within 5 min. Reasons for test termi-

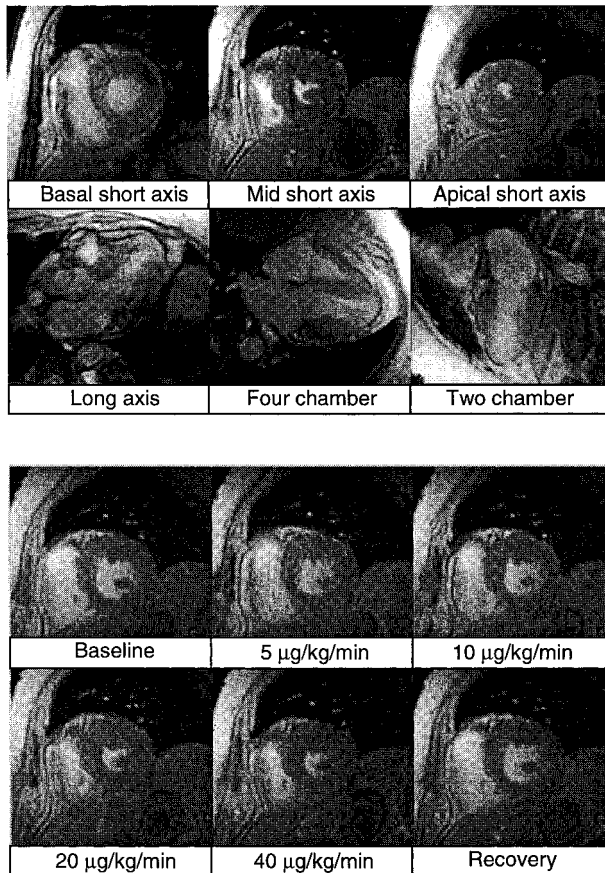


**Figure 1.** By overlapping the stages of reconstruction, transfer, and display, the time from end-of-acquisition to cine viewing is 25–35 sec. Using this technique, all six views of the left ventricle can be acquired and displayed in a 4 to 5-min dosing interval.

Copyright © Marcel Dekker, Inc. All rights reserved.



**Figure 2.** The full matrix of acquired cine-loops showing all eight doses from baseline (B) to recovery (R) and all six views. Display of all 48 cine-loops at once is neither feasible nor desirable. Instead, the user can select a row (all doses of a given view) or a column (all views of a given dose) and rapidly switch between desired selections.



**Figure 3.** The cine-display program allows viewing of all views of a particular dose (top: peak stress, 140 beats/min) or all doses of a particular view (bottom: mid-short axis). Rapid switching (<1 sec) is provided between desired viewing formats.

**Table 2**

*Clinical Characteristics of the Study Population*

| Characteristic               | Percentage |
|------------------------------|------------|
| Hypertension                 | 68         |
| Hypercholesteremia           | 56         |
| Diabetes                     | 38         |
| Smoker                       | 51         |
| Prior myocardial infarction  | 40         |
| Coronary artery bypass graft | 26         |
| Coronary angioplasty         | 23         |
| Angina                       | 60         |
| Atypical chest pain          | 4          |
| Dyspnea on exertion          | 40         |
| CHF I/II                     | 6          |
| CHF III                      | 1          |
| Family history               | 65         |

CHF, congestive heart failure.

nation are given in Table 3. No subject experienced myocardial infarction, ventricular fibrillation, or death during or immediately after stress testing.

During testing, 103 of 469 patients (22%) experienced angina, with only 26 of the 103 (6% of the study population) developing wall motion abnormalities indicative of ischemia. New wall motion abnormalities indicative of ischemia were found in 102 patients (22%), with 39 of these having the test terminated at an intermediate level of pharmacologic stress. The mean highest dose of dobutamine administered in these 39 early terminating patients was 20 µg/kg/min.

**DISCUSSION**

Abnormalities of LV contraction precede ST segment changes in patients with inducible myocardial ischemia

**Table 3**

*Reasons for Test Termination*

| Reason for Termination     | Number of Patients |
|----------------------------|--------------------|
| Achieved target heart rate | 207                |
| Positive test              | 102                |
| Maximum stress             | 75                 |
| Anxiety                    | 31                 |
| Arrhythmia                 | 20                 |
| Nausea, hypertension       | 16                 |
| New finding at baseline    | 15                 |
| Dyspnea                    | 3                  |

(8); therefore, rapid visualization of LV regional wall motion, similar to that implemented in stress echocardiography (9), can be used to detect inducible ischemia and thus safely monitor patients during cardiac stress testing. Imaging only at baseline and at peak stress without intermediate monitoring could increase the risk of myocardial infarction if inotropic (dobutamine) or chronotropic (atropine) agents are continuously administered to a patient experiencing inducible ischemia. Our results indicate that the combination of ECG monitoring of heart rate and rhythm along with visual assessment of LV contractility throughout the course of a stress test provides detection of the onset of ischemia and the ability to continue a test when chest discomfort is present without new wall motion abnormalities indicative of ischemia. With this imaging strategy, no patients developed myocardial infarction, ventricular fibrillation, or death. Imaging at intermediate doses was beneficial for 116 of the 469 patients in this study (25%) by permitting continuation of the test in 77 of the 103 with angina and providing early termination in 39 of the 102 with new wall motion abnormalities. Importantly, we stopped testing in 38% of our tests with inducible ischemia present at low or intermediate doses of dobutamine.

Three requirements were necessary to achieve the rapid visualization of LV contraction necessary to identify inducible ischemia. The first was a rapid imaging technique that provided the temporal resolution necessary to define the LV endocardial border at end-systole. High gradient strengths provided the ability to acquire fast gradient echo images with a repetition time of 12 to 14 msec that, combined with the use of segmented k-space acquisition and view sharing, provided a temporal resolution of 39–65 msec in patients at rest (heart rate, 55–95 beats/min) and 13–39 msec with heart rates of 95–170 beats/min. This imaging strategy allowed the assessment of endocardial thickening at 85% MPHRR for age, a heart rate response that has been shown to improve the diagnostic accuracy of other forms of noninvasive testing during exercise or pharmacologic-induced stress (10).

The second requirement was complete visualization of regional wall motion during a 4- to 5-min infusion interval. To achieve rapid visualization of each cine-loop, we initiated automatic transfer of the images from the scanner to the workstation at the end of each scan. The stages of image reconstruction, transfer, and display were overlapped in time, resulting in a delay of only 25–35 sec between acquisition of each slice and display of the cine-loop. This process allowed collection and display of all six views of the left ventricle well within the 4- to 5-min dosage interval used in our protocol.

The third requirement was the provision of a flexible display format suitable for complete rapid evaluation of LV contractility. The quad-screen format used in stress echocardiography was extended to provide six different views of the left ventricle (three short-axis views instead of one) and thus provide images of each segment of the left ventricle in at least two views. The ability to instantaneously switch between viewing formats (views or doses) proved valuable for detecting changes in endocardial thickening indicative of inducible ischemia.

Our data, supporting the near continuous visualization of LV wall motion during stress testing, are consistent with stress echocardiography data. As shown by Attenhofer et al. (11), visualization of all endocardial segments in multiple views throughout each stage of pharmacologic infusion yielded improved diagnostic accuracy for detecting inducible ischemia when compared with image review only at baseline and peak stress. In a review of thousands of stress echocardiograms by Geleijnse et al. (9), many patients develop chest pain during the procedure but have no evidence of inducible ischemia upon review of LV wall motion. Continuous review allows for the appropriate continuation of studies in this situation. Without continuous review, studies must be terminated upon the development of chest pain.

A potential modification of our imaging strategy would be the use of real-time echo planar imaging (12). With this modified strategy, six or more views of the heart could be collected in less than 1 min. Because a subsequent dose of dobutamine or atropine will not be delivered for several minutes, the additional time could be used to continuously monitor suspect wall segments in a manner similar to real-time echocardiography. However, there are potential limitations to real-time imaging during stress testing. First, gradient noise would interfere with the ability to converse with patients during testing. We find that talking to patients between doses encourages patient cooperation, when they otherwise might decide to terminate. Second, there is potential to generate very large amounts of image data, requiring further developments in hardware and software to appropriately manage and display the data for physicians during testing. Finally, real-time imaging would require high performance gradients that are available only on select MRI scanners. An advantage of the imaging strategy presented in this study is that it can be implemented on virtually any current 1.5-T system. Further research and development in this area may clarify some of these issues.

A limitation of our study is that we did not randomize patients to imaging at only baseline and peak stress versus continuous imaging. For this reason, our results are



observational. It is important to note, however, that our results suggest that conducting a randomized comparison could be hazardous, because continuation of inotropic and chronotropic stimulation in the setting of undetected inducible ischemia could promote an infarction. A related point is that it is presently unclear whether continuing the test in the presence of a small wall motion abnormality, potentially resulting in a greater response, would also result in additional useful diagnostic and prognostic information. Again, testing the value of continuing the test, aiming for a greater response, would likely be risky; hence, we chose to terminate the test in these cases, resulting in a very low complication rate.

In conclusion, our results indicate that rapid cine MRI and display of LV contraction throughout the course of testing was used to diagnosis inducible ischemia before peak stress in 38% of patients with positive tests. In addition, 22% of patients developed chest pain at low doses without inducible ischemia, and for these patients testing was continued safely. Our results suggest that imaging only at baseline and peak stress, rather than continuously during testing, could lead to premature test termination or, more importantly, expose patients to an unnecessary risk of myocardial infarction if inducible ischemia was not detected during the early stages of testing.

#### ACKNOWLEDGMENT

Supported in part by the Wake Forest University Baptist Medical Center Technology Development Fund (BG96-302) and by a grant from General Electric Medical Systems.

#### REFERENCES

- Nagel, E.; Lehmkuhl, H.B.; Bocksch, W.; Klein, C.; Vogel, U.; Frantz, E.; Ellmer, A.; Dreyse, S.; Fleck, E. Non-invasive Diagnosis of Ischemia-Induced Wall Motion Abnormalities With the Use of High-Dose Dobutamine Stress MRI. *Circulation* **1999**, *99*, 763–770.
- Hundley, W.G.; Hamilton, C.; Thomas, M.S.; Herrington, D.M.; Salido, T.B.; Kitzman, D.W.; Little, W.C.; Link, K.M. Utility of Fast Cine Magnetic Resonance Imaging and Display for the Detection of Myocardial Ischemia in Patients Not Well Suited for Second Harmonic Stress Echocardiography. *Circulation* **1999**, *100*, 1697–1702.
- Weigl, A.; Moshage, W.; Hentschel, D.; Schittenhelm, R.; Bachmann, K.; ECG Changes Caused by the Effect of Static Magnetic Fields of Nuclear Magnetic Resonance Tomography Using Magnets with a Field Power of 0.5 to 4.0 Tesla. *Zeitschr. Kardiol.* **1989**, *78*, 578–586.
- Beleslin, B.D.; Ostojic, M.; Stepanovic, J.; Dikic, A.D.; Stojkovic, S.; Medeljkovic, M.; Stankovic, G.; Petrasi-novic, Z.; Gojkovic, L.; Pkrajcic, Z.V.; Nedeljkovic, S. Stress Echocardiography in the Detection of Myocardial Ischemia: Head to Head Comparison of Exercise, Dobutamine, and Dipyridamole Tests. *Circulation* **1994**, *90*, 1168–1176.
- Rerkpattanapipat, P.; Link, K.M.; Hamilton, C.A.; Hundley, W.G.; Detecting Left Ventricular Myocardial Ischemia During Intravenous Dobutamine with Cardiovascular Magnetic Resonance Imaging (MRI). *J. Cardiovasc. Magn. Reson.* **2001**, *3*, 21–25.
- Schiller, N.B.; Shah, P.M.; Crawford, M.; DeMaria, A.; Devereux, R.; Feigenbaum, H.; Gutgesell, H.; Reicheck, N.; Sahn, D.; Schilger, I. Recommendations for Quantitation of the Left Ventricle by Two-Dimensional Echocardiography. *J. Am. Soc. Echocardiogr.* **1989**, *2*, 358–367.
- Hamilton, C.A.; Link, K.M.; Salido, T.W.; Thomas, M.; Grab, J.D.; Hundley, G. Near Real-Time Cardiac Cine-MR Monitoring During High-Dose Pharmacologic Stress Testing. *Radiology* **1998**, *209*, 229.
- Aroesty, J.M.; McKay, R.G.; Heller, G.V.; Royal, H.D.; Als, A.V.; Grossman, W. Simultaneous Assessment of Left Ventricular Systolic and Diastolic Dysfunction During Pacing-Induced Ischemia. *Circulation* **1985**, *71*, 889–900.
- Geleijnse, M.L.; Fioretti, P.M.; Roelandt, J.R.T.C. Methodology, Feasibility, Safety and Diagnostic Accuracy of Dobutamine Stress Echocardiography. *J. Am. Coll. Cardiol.* **1997**, *30*, 595–606.
- McNeill, A.J.; Fioretti, P.M.; El-Said, E.S.M; Salustri, A.; Forster, T.; Roelandt, J.R.T.C. Enhanced Sensitivity for Detection of Coronary Artery Disease by Addition of Atropine to Dopabutamine Stress Echocardiography. *Am. J. Cardiol.* **1992**, *70*, 41–46.
- Attenhofer, C.H.; Pellika, P.A.; Oh, J.K.; Roger, V.L.; McCully, R.B.; Shub, C.; Seward, J.B. Is Review of Videotape Necessary After Review of Digitized Cine-Loop Images in Stress Echocardiography? A prospective study in 306 patients. *J. Am. Soc. Echocardiogr.* **1997**, *10*, 179–184.
- Nagel, E.; Schneider, U.; Schalla, S.; Ibrahim, T.; Schnackenburg, B.; Bornstedt, A.; Klein, C.; Lehmkuhl, H.B.; Fleck, E. Magnetic Resonance Real-Time Imaging for the Evaluation of Left Ventricular Function. *J. Cardiovasc. Magn. Reson.* **2000**, *2*, 7–14.

Received August 10, 2000  
Accepted February 20, 2001

## **Request Permission or Order Reprints Instantly!**

Interested in copying and sharing this article? In most cases, U.S. Copyright Law requires that you get permission from the article's rightsholder before using copyrighted content.

All information and materials found in this article, including but not limited to text, trademarks, patents, logos, graphics and images (the "Materials"), are the copyrighted works and other forms of intellectual property of Marcel Dekker, Inc., or its licensors. All rights not expressly granted are reserved.

Get permission to lawfully reproduce and distribute the Materials or order reprints quickly and painlessly. Simply click on the "Request Permission/Reprints Here" link below and follow the instructions. Visit the [U.S. Copyright Office](#) for information on Fair Use limitations of U.S. copyright law. Please refer to The Association of American Publishers' (AAP) website for guidelines on [Fair Use in the Classroom](#).

The Materials are for your personal use only and cannot be reformatted, reposted, resold or distributed by electronic means or otherwise without permission from Marcel Dekker, Inc. Marcel Dekker, Inc. grants you the limited right to display the Materials only on your personal computer or personal wireless device, and to copy and download single copies of such Materials provided that any copyright, trademark or other notice appearing on such Materials is also retained by, displayed, copied or downloaded as part of the Materials and is not removed or obscured, and provided you do not edit, modify, alter or enhance the Materials. Please refer to our [Website User Agreement](#) for more details.

**[Order now!](#)**

Reprints of this article can also be ordered at

<http://www.dekker.com/servlet/product/DOI/101081JCMR100108582>