

ORIGINAL ARTICLE

Paramagnetic Agents

Myocardial Drug Distribution Pattern Following Intrapericardial Delivery: An MRI Analysis

John D. Gleason,^{1,2} Khanh P. Nguyen,³
Kraig V. Kissinger,³ Warren J. Manning,^{2,3,4}
and Richard L. Verrier^{2,3,*}

¹*Division of Health Sciences and Technology, Massachusetts Institute of Technology, Cambridge, Massachusetts*

²*Harvard Medical School, Boston, Massachusetts*

³*Department of Medicine, Cardiovascular Division, Beth Israel Deaconess Medical Center, Boston, Massachusetts*

⁴*Department of Radiology, Beth Israel Deaconess Medical Center, Boston, Massachusetts*

ABSTRACT

Objectives: The main goal was to gain insights into the pharmacokinetics of intrapericardial drug delivery using magnetic resonance (MR) imaging analysis and the extracellular MR contrast agent gadopentetate dimeglumine (Gd-DTPA) as a model.

Background: Recent development of catheter-based techniques to access the intact pericardial space has increased interest in intrapericardial delivery for local cardiac therapy. Distribution and myocardial penetration of intrapericardial agents are not well characterized.

Methods: The intact pericardial space was percutaneously accessed through the right atrial appendage in ten anesthetized pigs, following which 5 mL Gd-DTPA (N = 8) or normal saline as control (N = 2) were administered. Animals were sacrificed at 1, 3, 3.5, 5, or 8 hr. The whole heart was excised, washed with normal saline, and the chambers distended with saline-filled bags. Myocardial penetration of Gd-DTPA was analyzed by a series of short-axis T1-weighted turbo-spin-echo MR images.

*Corresponding author. Beth Israel Deaconess Medical Center, One Autumn Street, W/KN-521, Boston, MA 02215. Fax: (617) 632-7675; E-mail: rverrier@caregroup.harvard.edu

Results: At 1, 3, and 3.5 hr after Gd-DTPA, a uniform ring of enhancement was found along the epicardium, with a depth density related to time after administration. No contrast ring was visible at 5 or 8 hr or in control animals. Transmural myocardial T1 values obtained 5 hr after Gd-DTPA administration were reduced, suggesting that Gd-DTPA had penetrated uniformly throughout the myocardium.

Conclusions: Intrapericardial administration results in relatively uniform distribution of an agent across the ventricular epicardium. The depth of penetration is consistent with functional evidence that epicardial structures can be targeted by this technique.

Key Words: Pharmacokinetics; Magnetic resonance imaging; Pericardium

The pericardial space is an efficient site for delivery of gene vectors,^[1] growth factors,^[2] and agents to reduce ventricular^[3–5] and atrial arrhythmias,^[6,7] dilate coronary arteries^[8] and inhibit neointimal proliferation^[9] in experimental animals with an intact pericardial sac. These findings have increased interest in novel percutaneous catheter-based techniques for accessing the pericardial space and epicardial surface for localized drug delivery.^[1,10,11] Previous observations noted that the distribution of fluid in the intact pericardial sac is nonuniform^[12,13] and that penetration of agents may be limited by the epicardium.^[14,15] As no detailed study of the myocardial distribution pattern of intrapericardial agents has been published, we sought to characterize myocardial penetration using an intrapericardially administered magnetic resonance (MR) contrast agent.

METHODS

The study was conducted according to the National Institutes of Health standards and conformed to the “Position of the American Heart Association on Research Animal Use.” The experimental protocol was approved by the Harvard Medical Area Standing Committee on Animal Use.

Ten juvenile farm pigs (25–35 kg) were preanesthetized (telazol, 4.7 mg/kg, i.m., and xylazine, 2.2 mg/kg, i.m.), anesthetized (alpha-chloralose, 100 mg/kg, i.v., bolus plus 40 mg/kg/hr, i.v.) and ventilated (Harvard ventilator). Intrapericardial access was achieved under fluoroscopic guidance with previously published methods.^[10] An 8F multipurpose guide catheter was advanced through an 8F femoral vein sheath into the right atrial appendage. The appendage was pierced with a

0.036-cm guidewire protruding ~1 cm from a 0.097-cm infusion catheter. The guidewire was removed and the infusion catheter was advanced to the apex of the heart. Withdrawal of pericardial fluid (1 mL) confirmed intrapericardial location. Twelve-lead EKGs and arterial blood pressure, recorded through a femoral or carotid arterial sheath, were monitored (Prucka CardioLab® System, GE Medical Systems, Milwaukee, WI).

In eight animals, 0.5-M gadopentetate dimeglumine (Gd-DTPA, 5-mL, Magnevist, Berlex) was injected intrapericardially. Animals were sacrificed (potassium chloride, 60 mL bolus, i.v.) after remaining in the unchanged supine position for 1 ($n = 1$), 3 ($n = 1$), 3.5 ($n = 3$), 5 ($n = 2$), or 8 ($n = 1$) hr. Normal saline (5 mL) was injected intrapericardially in two control animals that were then sacrificed at 8 hr. The hearts of all animals were rapidly extirpated, the pericardium removed and the epicardial surface rinsed with normal saline. Saline-filled latex gloves were inserted into the left and right ventricular cavities to distend the chambers, thereby improving visualization.

To evaluate the distribution of contrast agent, excised hearts were imaged with a commercial 1.5 T whole-body MR scanner (ACS-NT, Philips Medical Systems, Best, The Netherlands) configured with PowerTrak 6000 gradient system (21 mT/m, 100 T/m/sec). A standard head coil was used as the radiofrequency receiver. A 15-sec segmented gradient echo sequence (nine slices, three in each plane in sagittal, coronal, and transverse orientations) was performed for localization. Single- or double-oblique slices were subsequently acquired to determine the short-axis orientation of the left ventricle. Left-ventricular short-axis T1-weighted turbo-spin echo images were acquired (TR = 450 msec, TE = 16 msec, ETL = 3, FOV = 150 mm × 200 mm, Matrix = 410 × 512) from 164-mm slices

with 1-mm interslice gap. Signal from epicardial fat was suppressed by spectral presaturation. The penetration depth of Gd-DTPA, as visualized on the short axis T1 weighted images, was evaluated using a profile of signal intensity along a line, thereby providing a quantitative measure not influenced by window and level settings. T1 values were measured on calculated T1 images derived from an interleaved spin echo (TR = 760 msec)/inversion recovery (TR = 2290 msec, delay = 370 msec) sequence in two animals (5-hr Gd-DTPA; saline control). Four echoes were collected at 50, 100, 150, and 200 msec. One 7-mm slice was acquired in the short-axis orientation at a mid-ventricular level with a 2 mm × 2 mm in-plane resolution. Myocardial penetration was measured in terms of means ± SEM.

RESULTS

No significant ECG, heart rate, or arterial blood pressure changes were observed at any time following intrapericardial administration of Gd-DTPA or saline.

The short-axis MR images from animals sacrificed 1, 3, and 3.5 hr after Gd-DTPA showed a relatively uniform ring of enhancement around the ventricular myocardium (Fig. 1), with depth of penetration directly related to time from Gd-DTPA administration to animal sacrifice. The ring thicknesses measured at the right ventricular free wall and the anterior, inferior and lateral left ventricular walls were 2.7 ± 0.1 , 2.4 ± 0.2 , and 3.3 ± 0.2 mm (mean ± SEM) at 1, 3, and 3.5 hr, respectively. No contrast enhancement pattern was seen in the interventricular septum. In some experiments, the enhancement penetrated more deeply in the area of the interventricular groove. No visible contrast ring was found in the hearts of pigs sacrificed 5 or 8 hr after Gd-DTPA or any in saline control heart. However, transmural myocardial and septal T1 values at 5 hr after Gd-DTPA were substantially lower (600–900 msec) than those of a control animal (at 1000–2000 msec) indicating the presence of Gd-DTPA throughout the myocardial wall (Fig. 2).

DISCUSSION

In this study, we sought to determine whether intrapericardial agents could penetrate uniformly and completely into the ventricular myocardium, despite reports of uneven pericardial fluid distribution in the intact sac^[12,13] and of epicardial barriers to penetration.^[14,15] Heterogeneous absorption of intrapericardial agents could limit the clinical utility of the intrapericardial

approach for targeted delivery of antiarrhythmic agents, because it would be expected to increase electrical dispersion and result in proarrhythmia. Santamore et al.^[12] found that 15 min following intrapericardial delivery, lissamine green dye had accumulated over the interventricular and atrioventricular grooves with little or none visible over the right and left ventricular free walls. More recently, Stoll et al.^[13] determined that immediately following intrapericardial administration, ¹³¹I-labeled albumin diazeniumdiolate collected largely laterally and inferoapically. These observations confirm the nonuniform distribution of fluid volumes within the closed sac but do not address penetration by an intrapericardial agent into myocardial tissue.

The single published report on pericardial fluid absorption yielded inconsistent results. Deep staining by methylene blue of the ventricular groove but only patchy staining of the ventricular surface and no apparent penetration of the ventricular endocardium were found < 2 hr following injection into the intact pericardial space

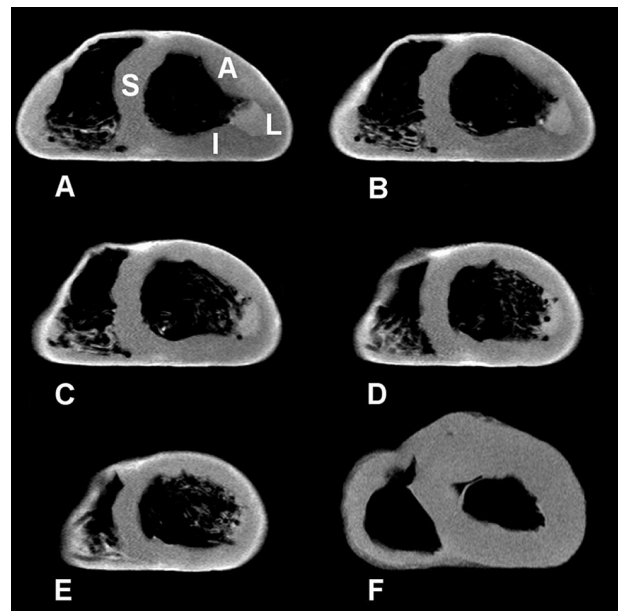


Figure 1. Short-axis T1-weighted MR images of excised hearts. (A–E): Representative slices of a heart excised 3.5 hr following intrapericardial infusion of Gd-DTPA. The bright, uniform ring of enhancement around the epicardial surface is the result of decreased T1 relaxation time due to Gd-DTPA penetration. No enhancement is seen along either side of the interventricular septum (S). (F): By comparison, the control heart, with saline only, shows no contrast rim at 8 hr after intrapericardial saline. L = lateral wall, A = anterior wall, I = inferior wall, S = septum.

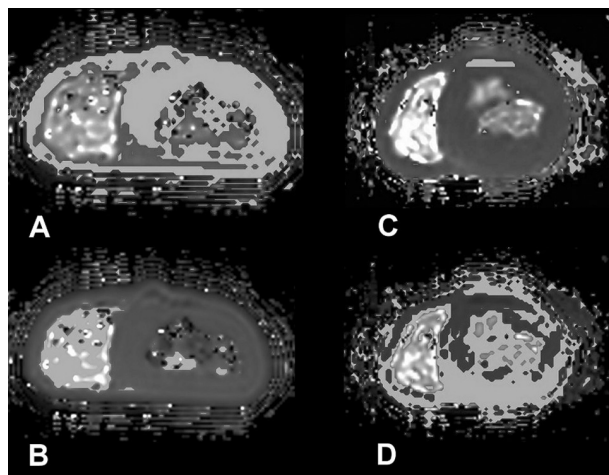


Figure 2. Short-axis T1-weighted MR images of hearts excised 5 hr following intrapericardial infusion of Gd-DTPA. (A, B): most of the myocardium, including the septum, has T1 values in the range of 600–900 msec (light gray areas of Panel A), consistent with the presence of Gd-DTPA throughout the tissue, rather than 1000–2000 msec (light gray areas, Panel B), indicating areas without Gd-DTPA. In the saline control heart, without Gd-DTPA, none of the myocardium has T1 values in the 600–900 msec range (light gray areas, Panel C) with most in the 1000–2000 msec range (light gray areas, Panel D).

of rabbits.^[14] In the same study, more uniform methylene-blue staining was observed in a single experiment in a feline with a pericardial cradle, although the right ventricle appeared more deeply stained than the left.

This is the first study to analyze and demonstrate the uniform penetration by an intrapericardial agent into the ventricular myocardium. We hypothesize that the thin continuous fluid layer around the heart, combined with its beating motion, provides contact with a uniform solute concentration, thereby allowing homogenous absorption. Gd-DTPA penetrated most rapidly during the first hour after injection and within 3.5 hr had penetrated into the mid-myocardium. No contrast ring of enhancement was evident at 5 or 8 hr, prompting us to perform the T1 studies to determine if penetration was uniform at that time. Myocardial T1, a measure of tissue relaxation time shortened by Gd-DTPA, was lower at 5 hr after Gd-DTPA than in a saline control heart, suggesting that Gd-DTPA had fully and uniformly penetrated into the ventricular myocardium. It is not known, however, how deeply therapeutically relevant amounts of an intrapericardial agent would distribute, and particular agents may differ in their penetration of the myocardium following intrapericardial administration. The limited

information available on drug penetration from the epicardium derives from the study of Avitall et al.,^[15] who found epicardial procainamide insufficient to penetrate myocardial tissue without iontophoresis. However, the protocol involved only 10 min of drug delivery from a patch followed by blotting the heart surface until dry.

The time course and depth of penetration are both affected by the agent's pharmacologic properties. As Gd-DTPA is not subject to metabolism within the tissue, its duration would be expected to be greater than that of a readily metabolized drug. Indeed, we observed that intrapericardial nitroglycerin dilates the coronary artery for 15 min^[8] and exerts an antiarrhythmic effect for up to 75 min.^[4]

CONCLUSIONS

In this imaging study, we demonstrate that intrapericardially administered agents encounter sufficient mixing within pericardial fluid to penetrate the epicardial surface of the heart uniformly from the continuous thin fluid layer over the epicardium. The depth of penetration, achieved without iontophoresis, was directly related to time after intrapericardial drug administration. Our findings are consistent with functional evidence that passive penetration by intrapericardially administered agents is sufficient to affect the epicardial coronary vessels,^[8a] the cardiac nerve supply to suppress atrial^[6,7] and ventricular arrhythmia,^[3,4] and the cells responsible for the epicardially dense transient outward current.^[5,17] These studies support previous evidence of effective arrhythmia suppression by epicardially administered agents in open-chest animals.^[15,18,19] These observations indicate that whereas the presence of uneven transmural penetration gradients from epicardium to endocardium and limited access to the interventricular septum may result in the potential for proarrhythmia due to nonuniform effect on refractoriness, the net effect of an intrapericardial agent can be antiarrhythmic if it acts on specific anatomical structures. In the final analysis, intrapericardial agents may be employed not only to target the heart as a whole but individual sites for therapeutic benefit.

ABBREVIATIONS

Gd-DTPA	Gadopentetate dimeglumine
MR	Magnetic resonance

ACKNOWLEDGMENTS

This study was supported in part by grants P01 ES09825 from National Institutes of Environmental Health Sciences and R01 HL63968 from Heart, Lung and Blood Institute, National Institutes of Health, Bethesda, MD.

REFERENCES

1. March, K.L.; Woody, M.; Mehdi, K.; Zipes, D.P.; Brantly, M.; Trapnell, B.C. Efficient In Vivo Catheter-Based Pericardial Gene Transfer Mediated by Adenoviral Vectors. *Clin. Cardiol.* **1999**, *22*, I-23–I-29.
- 1a. Zhang, J.C.L.; Wood, Y.J.; Chen, J.-A.; Sweeney, H.L. Efficient Transmural Cardiac Gene Transfer by Intrapericardial Injection in Neonatal Mice. *J. Mol. Cell. Cardiol.* **1999**, *31*, 721–732.
2. Lazarous, D.F.; Shou, M.; Stiber, J.A.; Dadhania, D.M.; Thirumurti, V.; Hodge, E.; Unger, E.F. Pharmacodynamics of Basic Fibroblast Growth Factor: Route of Administration Determines Myocardial and Systemic Distribution. *Cardiovasc. Res.* **1997**, *36*, 78–85.
- 2a. Laham, R.J.; Rezaee, M.; Post, M.; Novicki, D.; Sellke, F.W.; Pearlman, J.D.; Simons, M.; Hung, D. Intrapericardial Delivery of Fibroblast Growth Factor-2 Induces Neovascularization in a Porcine Model of Chronic Myocardial Ischemia. *J. Pharmacol. Exp. Ther.* **2000**, *292*, 795–802.
3. Moreno, R.; Waxman, S.; Rowe, K.; Verrier, R.L. Intrapericardial Beta-Adrenergic Blockade with Esmolol Exerts a Potent Antitachycardic Effect Without Depressing Contractility. *J. Cardiovasc. Pharmacol.* **2000**, *36*, 722–727.
4. Kumar, K.; Waxman, S.; Wellenius, G.A.; Nguyen, K.; Nearing, B.D.; Verrier, R.L. Percutaneous Nitroglycerin Administration into the Intact Pericardial Space Suppresses Ischemia-Induced Ventricular Arrhythmias in Closed-Chest Pigs [Abstract]. *Pacing Clin. Electrophysiol.* **2000**, *23*, 730.
5. Kumar, K.; Nguyen, K.P.; Wellenius, G.A.; Nearing, B.D.; Verrier, R.L. Intrapericardial Blockade of Transient Outward Current (Ito) Suppresses Ischemia-Induced T-Wave Alternans in Closed-Chest Pigs [Abstract]. *Pacing Clin. Electrophysiol.* **2001**, *24*, 544.
6. Ujhelyi, M.R.; Hadsall, K.Z.; Euler, D.E.; Mehra, R. Intrapericardial Therapeutics: A Pharmacodynamic and Pharmacokinetic Comparison Between Pericardial and Intravenous Procainamide Delivery. *J. Cardiovasc. Electrophysiol.* **2002**, *13*, 605–611.
7. Gleason, J.D.; Nguyen, K.P.; Wellenius, G.A.; Kirkham, J.C.; Verrier, R.L. Intrapericardial Procaine Produces Marked and Prolonged Reduction in Vulnerability to Vagally Mediated Atrial Fibrillation [Abstract]. *Pacing Clin. Electrophysiol.* **2001**, *24*, 600.
8. Waxman, S.; Moreno, R.; Rowe, K.A.; Verrier, R.L. Persistent Primary Coronary Dilation Induced by Transatrial Delivery of Nitroglycerin into the Pericardial Space: A Novel Approach for Local Cardiac Drug Delivery. *J. Am. Coll. Cardiol.* **1999**, *33*, 2073–2077.
- 8a. Baek, S.A.; Hrabie, J.A.; Keefer, L.K.; Dongming, H.; Fineberg, N.; Rodney, R.; March, K.L. Augmentation of Intrapericardial Nitric Oxide Level by a Prolonged-Release Nitric Oxide Donor Reduces Luminal Narrowing After Porcine Coronary Angioplasty. *Circulation* **2002**, *105*, 2779–2784.
9. Hou, D.; Rogers, P.I.; Toleikis, P.M.; Hunter, W.; March, K.L. Intrapericardial Paclitaxel Delivery Inhibits Neointimal Proliferation and Promotes Arterial Enlargement After Porcine Coronary Overstretch. *Circulation* **2000**, *102*, 1575–1581.
10. Verrier, R.L.; Waxman, S.; Lovett, E.G.; Moreno, R. Transatrial Access to the Normal Pericardial Space: A Novel Approach for Diagnostic Sampling, Pericardiocentesis, and Therapeutic Interventions. *Circulation* **1998**, *98*, 2331–2333.
11. Waxman, S.; Pulerwitz, T.C.; Rowe, K.A.; Quist, W.C.; Verrier, R.L. Preclinical Safety Testing of Percutaneous Transatrial Access to the Normal Pericardial Space for Local Cardiac Drug Delivery and Diagnostic Sampling. *Catheter. Cardiovasc. Interv.* **2000**, *49*, 472–477.
- 11a. Hermans, J.J.R.; Van Essen, H.; Struijker-Boudier, H.A.J.; Johnson, R.M.; Theeuwes, F.; Smits, J.F.M. Pharmacokinetic Advantage of Intrapericardially Applied Substances in the Rat. *JPET* **2002**, *301*, 672–678.
12. Santamore, W.P.; Constantinescu, M.S.; Bogen, D.; Johnston, W.E. Nonuniform Distribution of Normal Pericardial Fluid. *Basic Res. Cardiol.* **1990**, *85*, 541–549.
13. Stoll, H.-P.; Carlson, K.; Keefer, L.K.; Hrabie, J.A.; March, K.L. Pharmacokinetics and Consistency of Pericardial Delivery Directed to Coronary Arteries: Direct Comparison with Endoluminal Delivery. *Clin. Cardiol.* **1999**, *22*, I-10–I-16.
14. Drinker, C.K.; Field, M.E. Absorption from the Pericardial Cavity. *J. Exp. Med.* **1931**, *53*, 143–150.
15. Avitall, B.; Hare, J.; Zander, G.; Bockoff, C.; Tchou, P.; Jazayeri, M.; Akhtar, M. Iontophoretic Transmyocardial Drug Delivery: A Novel Approach to Antiarrhythmic Drug Therapy. *Circulation* **1992**, *85*, 1582–1593.
16. Task Force of the Working Group on Arrhythmias of the European Society of Cardiology; The Sicilian Gambit: A New Approach to the Classification of Drugs Based on Their Actions and Arrhythmogenic Mechanisms. *Circulation* **1991**, *84*, 1831–1851.
17. Miyazaki, T.; Zipes, D.P. Pericardial Prostaglandin Biosynthesis Prevents the Increased Incidence of Reperfusion-Induced Ventricular Fibrillation Produced

- by Efferent Sympathetic Stimulation in Dogs. *Circulation* **1990**, 82, 1008–1019.
18. Ayers, G.M.; Rho, T.H.; Ben-David, J.; Besch, H.R.; Zipes, D.P. Amiodarone Instilled into the Canine Pericardial Sac Migrates Transmurally to Produce Electrophysiologic Effects and Suppress Atrial Fibrillation. *J. Cardiovasc. Electrophysiol.* **1996**, 7, 713–721.
 19. Fei, L.; Baron, A.D.; Henry, D.P.; Zipes, D.P. Intrapericardial Delivery of L-Arginine Reduces the Increased Severity of Ventricular Arrhythmias During Sympathetic Stimulation in Dogs with Acute Coronary Occlusion. Nitric Oxide Modulates Sympathetic Effects on Ventricular Electrophysiological Properties. *Circulation* **1997**, 96, 4044–4049.

Received November 6, 2001

Accepted April 24, 2002