

## CORONARY ARTERY DISEASE

# Coronary flow evaluation by TIMI frame count and magnetic resonance flow velocity in patients with coronary artery ectasia

SOPHIE I. MAVROGENI, M.D., F.E.S.C.,<sup>1,\*</sup> ATHANASSIOS MANGINAS,<sup>1</sup> EMMANOUIL PAPADAKIS,<sup>1</sup> MAROUSO DOUSKOU,<sup>2</sup> DIMOSTHENIS COKKINOS,<sup>1</sup> VASILIKI KATSIVA,<sup>2</sup> STEFANOS FOUSSAS,<sup>1</sup> VASILIOS VOUDRIS,<sup>1</sup> ALEXIOS GIAKOUMELOS,<sup>2</sup> IOANNIS SEIMENIS,<sup>3</sup> PANAGIOTIS BARAS,<sup>3</sup> and DENNIS V. COKKINOS<sup>1</sup>

<sup>1</sup>Onassis Cardiac Surgery Center, Athens, Greece

<sup>2</sup>Bioatriki MRI Unit, Athens, Greece

<sup>3</sup>Philips Hellas Medical Systems, Athens, Greece

**Purpose.** Coronary artery ectasia (CAE) is defined as a dilatation of an arterial segment to a diameter at least 1.5 times that of the adjacent artery. It is characterized by slow flow, predisposing to thrombosis. The TIMI frame count (TFC) technique has been successfully used for the assessment of coronary flow velocity using coronary angiograms (CA). Our aim was to compare TFC with magnetic resonance peak flow velocity (PFV) for the evaluation of the coronary flow in patients with CAE. **Methods.** Fifteen male patients with CAE, aged 45–60 yrs, and 15 age-matched male controls were studied by both techniques. Only patients without coronary obstructive disease were included. Magnetic resonance coronary angiography (MRA) was performed with a 1.5T scanner. The most ectatic part of the proximal 1/3 of the vessel involved was examined. Velocity-encoded MR images were acquired in a double oblique imaging plane, which was perpendicular to the same ectatic segment. The findings were compared with TFC results. **Results.** Ten patients had RCA ectasia and five LAD ectasia. In CAE patients, peak flow velocity was  $10.7 \pm 1.4$  cm/sec in RCA and  $11.4 \pm 2.3$  cm/sec in LAD. TFC was  $42.9 \pm 7.4$  in RCA and  $52.0 \pm 20.1$  in LAD. In controls, peak flow velocity was  $18.1 \pm 1.9$  in RCA and  $21.0 \pm 1.7$  cm/sec in LAD. TFC was  $20.4 \pm 1.59$  in RCA and  $19.8 \pm 1.12$  in LAD. Controls had significantly higher peak flow velocity ( $p < 0.001$ ) and lower TFC ( $p < 0.001$ ) in both RCA and LAD, compared to patients with CAE. In patients with CAE, there was a negative correlation between PFV and TFC measurements ( $r = -0.74$ ,  $p < 0.001$ ). **Conclusion.** Coronary flow in CAE patients can be assessed both by TFC and PFV. The noninvasive nature of PFV gives the opportunity for serial, easily repeatable, flow evaluation in these patients.

**Key Words:** TIMI frame count; Flow velocity; Magnetic resonance; Coronary ectasia

## 1. Introduction

Coronary artery ectasia (CAE) or aneurysmal coronary artery disease is defined as a dilatation of an arterial segment to a diameter at least 1.5 times that of the adjacent normal artery (1–3). It is found in up to 5% of angiographic and from 0.22% to 1.4% of autopsy series (4–7). Coronary artery ectasia or aneurysm is attributed to atherosclerosis in 50% of cases, 20% to 30% have been considered congenital in origin, and 10% to 20% of CAE cases have been described in association with inflammatory or connective tissue diseases.

The great majority of these patients has co-existent coronary artery disease (2, 8). Isolated CAE, in which coronary artery stenosis, valvular heart disease, and other cardiac disorders are not present, comprises a small portion of the total of CAE cases with an incidence of 0.1% to 0.79% (7, 9).

The clinical presentation of CAE includes typical exercise-induced angina pectoris and myocardial infarction either due to repeated dissemination of microemboli to segments distal to ectasia or due to thrombotic occlusion of the dilated vessel (9–11). Slow flow of the coronary artery, demonstrated in previous studies, may be a causative factor (3, 12). Patients without co-existing obstructive disease, termed as pure ectasia, have a more benign course but still a picture of a previous myocardial infarction is seen in 39% of them (13). Recently, exercise-induced myocardial ischemia has been documented in isolated CAE, suggesting impaired epicardial flow as a possible cause of coronary insufficiency (12, 22).

Received 9 October 2004; accepted 18 January 2005.

\*Address correspondence to Sophie I. Mavrogeni, M.D., F.E.S.C., 50 Esperou St., 175-61 P. Faliro, Athens, Greece; Fax: +30-210-98-82-797; E-mail: soma@aias.gr

The correct follow-up of ectatic vessels is hampered by the need for repeat angiograms. The TIMI frame count (TFC) method is a simple, inexpensive, reproducible, objective, and quantitative index of the “average” coronary flow velocity along the target coronary artery, measured using X-ray coronary angiography. Recently, magnetic resonance angiography (MRA) has been used for the non-invasive evaluation of the proximal part of the coronaries (14, 15). Magnetic resonance can also facilitate the non-invasive estimation of coronary artery blood flow velocity (16, 17).

The purpose of this study was to compare peak coronary flow velocity (PFV), measured by magnetic resonance angiography, with the TIMI frame count technique, using coronary angiography, for the evaluation of the coronary flow in a population with pure ectasia and in a group of age- and sex-matched controls.

## 2. Methods

### 2.1. Study population

Fifteen male patients, aged 45–60 years, with pure coronary ectasia (without coronary obstruction) documented by coronary x-ray angiography, were studied in a cross-sectional study. All of them had a history of chest pain, smoking, and hyperlipidemia. Patients were ineligible for enrollment if they had history of percutaneous coronary intervention prior myocardial infarction or known contraindication for MRI.

Fifteen male subjects with angiographic documentation of absence of significant stenosis and CAE, matched for age with the patients in the CAE group, served as controls. The indication for coronary angiography in the control subjects was either chest pain or evaluation of the coronary arteries in patients scheduled for valve surgery. These subjects were selected over the same time interval as the patients with CAE. An informed consent was obtained from all subjects, and the study was approved by the institutional ethics committee.

### 2.2. Quantitative coronary angiography

The indications for coronary angiography in the patient population were chest pain and a stress test suggestive of myocardial ischemia or both. Coronary angiography was routinely performed by the Judkins method without the use of nitroglycerin. According to the classification of Markis et al. (5), only patients with type 3 ectasia (diffuse ectasia of 1 vessel only) were included in the study. Using quantitative coronary angiography (QCA), the diameter of the most ectatic part of the proximal 1/3 of the vessel involved was measured and compared with MRA. Quantitative coronary angiography was performed by an observer blinded to the MRI results, using the guiding catheter as a calibration factor. The selected end-diastolic frames were magnified, digitized, and analyzed

off-line with the QCA imaging system (CMS, MEDIS, Leiden, The Netherlands). Automatic contour detection was performed with the geometric edge-differentiation technique according to a previously validated method (18).

### 2.3. TIMI frame count technique

The TIMI frame count (TFC), as introduced by Gibson, is the number of cine-frames required for contrast material to first reach standard distal anatomical landmarks of the coronary tree during conventional coronary angiography (19). Consequently, the slower the flow, the higher the TFC values. By definition, it cannot measure spot flow velocities; thus, it may be performed without lesion instrumentation. It has no clear relation to the catheter size, heart rate, or blood pressure, and difference in injection rates between angiographers results in < 2 frames of variability (20). In conjunction with appropriate hyperemic stimuli, this method can be also used reliably to estimate the coronary flow velocity reserve (21). The TFC in each angiogram was calculated as the mean value obtained by two angiographers. The inter- and intra-observer variability for baseline TFC was 2% and 1.5% respectively.

### 2.4. Magnetic resonance angiography

All fifteen patients that were diagnosed by coronary x-ray angiography as having CAE and controls underwent coronary MRA without the use of nitrates. Nitrates are contraindicated in patients with CAE because they may lower the ischemic threshold.

The MR examination was performed using a 1.5 T Philips Intera CV MR scanner (Philips, Best, the Netherlands) and a five-element cardiac phased array coil. The first localizing scan employed a multi-stack and multi-slice, segmented k-space gradient-echo sequence for localization of the heart and diaphragm in three orthogonal planes (transverse, sagittal, and coronal). To identify the proximal parts of the right and left coronary artery systems, a transverse ECG-triggered, three-dimensional segmented echo pulse sequence with EPI: Echo-Planar Imaging readout was used to cover the region from the apex of the left ventricle to the pulmonary artery (15). An ECG-triggered, three-dimensional segmented k-space gradient-echo pulse sequence (TE = 2.1 ms, TR = 7.5 ms, flip angle = 30°, eff. slice thickness = 1.5 mm) was then planned to cover the longest possible length of the ectatic vessel. The sequence employed a T2-weighted preparation prepulse and a frequency selective fat-saturation pre-pulse to enhance “white blood” contrast of the coronary arteries while data acquisition was performed in mid-diastole. Three-dimensional scans were carried out with the patient free breathing using a 2D real time navigator beam, properly placed on the patients’ right hemidiaphragm for respiratory motion tracking and gating (an acceptance window of 5 mm was used). Source images

obtained were used to derive multi-planar reconstructions (MPR) along the vessel path on an image processing workstation. Source images and MPRs were evaluated by two independent observers aiming at identifying the ectatic parts (long axis views). The diameter of the proximal most ectatic segment of each vessel was measured as the Full Width Half Maximum of a signal intensity profile located perpendicular to the vessel long axis. Multiple measurements were made either at different points across the ectatic segment or in adjacent source images depicting the same ectatic part in order to ensure that the maximum diameter was determined.

### 2.5. Magnetic resonance flow velocity

Following the coronary MRA, velocity-encoded MR images were acquired in a double oblique imaging plane, which was perpendicular to the most ectatic segment of the proximal part of the coronary artery involved. The sequence used was a 2D, segmented k-space gradient-echo sequence with a TE of 4.6 ms, a TR of 7.5 ms, a flip angle of  $26^\circ$ , a slice thickness of 5 mm, an in-plane spatial resolution of  $1.5 \text{ mm} \times 1.5 \text{ mm}$ , 2 signal averages, 4 views per segment, and a velocity window of  $\pm 40 \text{ cm/sec}$ . A frequency selective fat-saturation prepulse was employed. Scans were carried out with the patient free breathing using respiratory triggering and a 2D real time navigator beam for slice tracking. Retrospective ECG triggering from the QRS complex was implemented and 12–20 temporal phases per RR cycle were obtained, depending on patient's heart rate. Magnitude and phase-difference velocity-encoded images were derived using a view sharing reconstruction (Fig. 1). Image analysis was performed off-line on a dedicated analysis workstation by two independent observers. Images were analyzed by placing on the magnitude image a small ROI consisting of  $2 \times 2$  pixels in the arterial lumen and a large ROI on myocardium adjacent to or surrounding the coronary artery. These ROIs were copied to the corresponding phase-difference image and

corrected peak blood flow velocity in the coronary artery, in comparison to adjacent myocardium, was calculated for each cardiac phase. The highest peak velocity during diastole was defined as the diastolic peak velocity (cm/sec). Intra- and inter-observer variability for PFV was 2% and 2.5% respectively.

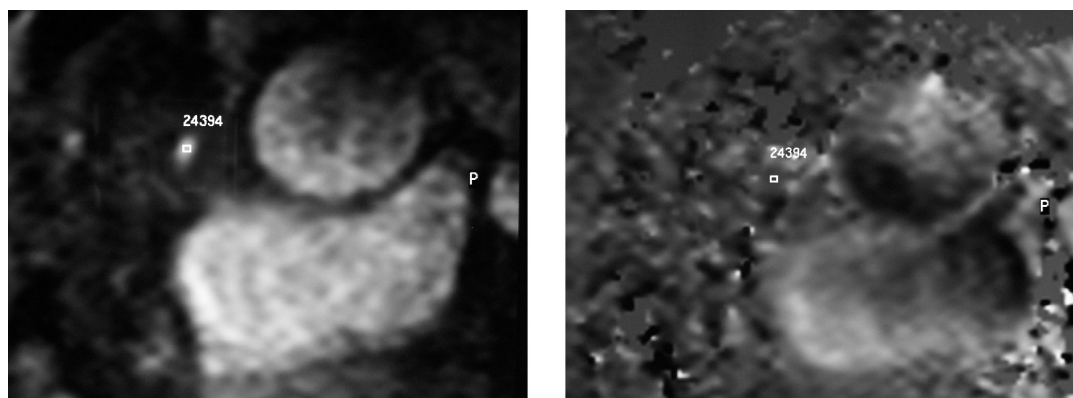
All CAE patients and controls completed magnetic resonance angiography and velocity flow measurement without complications. The mean total magnetic resonance scanning time (including scout imaging) was 60 minutes (range 50 to 70). Coronary magnetic resonance angiography was performed within 2 days (range: 1–4) after the coronary angiography. All subjects were in the same medication; no new clinical events were observed and no interventions were performed at the interim period. There was no difference in heart rate and blood pressure between the CA and MRA examinations (HR:  $89.0 \pm 9.6$  vs.  $84.3 \pm 9.2$  bpm, BPsystolic:  $119.6 \pm 8.5$  vs.  $116.3 \pm 10.0$  mmHg and BPdiastolic:  $79.3 \pm 4.9$  vs.  $76.3 \pm 6.1$  mmHg, respectively).

### 2.6. Statistical analysis

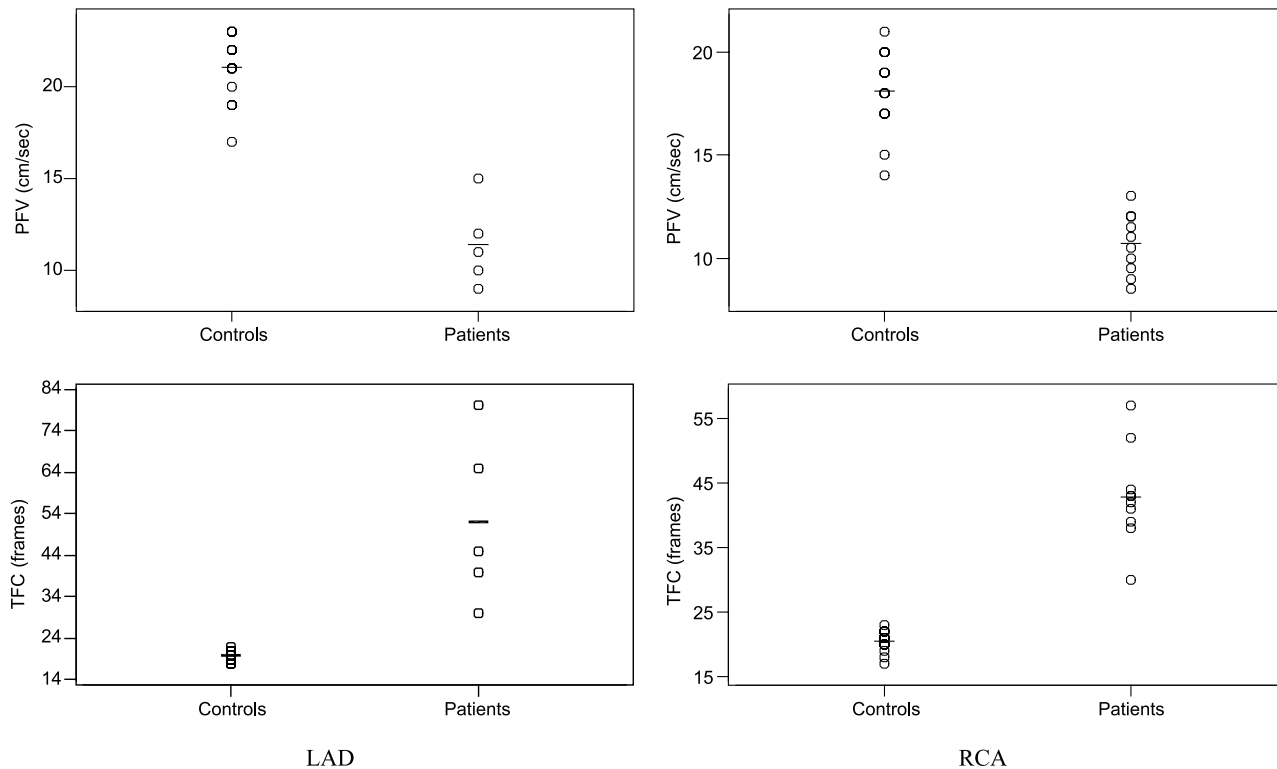
All measurements were expressed as mean  $\pm$  standard deviation. Statistical significance of the differences between results obtained from the used methods was investigated with the paired student's *t*-test. Correlation between QCA and MRA data and between TFC and PFV was sought with Pearson's correlation coefficient. Statistical significance was considered for  $p < 0.05$ .

## 3. Results

The average length of continuously visualized LM, LAD, LCx and RCA by MRA was  $2.5 \pm 0.3$ ,  $5.8 \pm 0.8$ ,  $3.9 \pm 1.0$  and  $7.2 \pm 1.2$  cm, respectively. Ten patients had RCA and five LAD ectasia. No LM or LCx ectasia was found.



**Figure 1.** Magnitude (left) and phase-difference (right) velocity encoded images acquired perpendicular to the proximal, most ectatic part of the RCA at a mid-diastolic phase (the ROI drawn highlights the entire RCA lumen).



**Figure 2.** Lower PFV ( $p < 0.001$ ) and higher TFC ( $p < 0.001$ ) measurements in patients with CAE compared to controls in both RCA and LAD (horizontal lines indicate mean values).

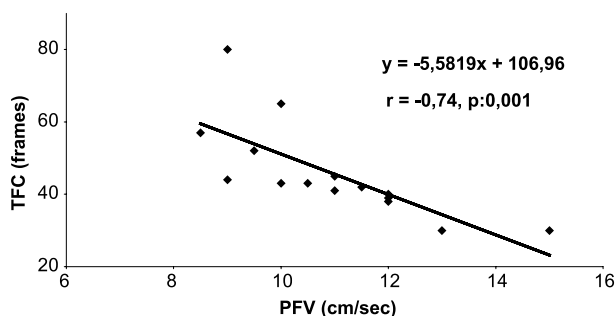
In patients with CAE, the MRA measurements of the diameter of the proximal most ectatic part of each vessel were  $5.3 \pm 0.7$  mm for RCA ( $n = 10$ ) and  $4.8 \pm 0.4$  mm for LAD ( $n = 5$ ). The QCA measurements of the diameter of the proximal most ectatic part of each vessel were  $5.2 \pm 0.7$  mm for RCA and  $4.9 \pm 0.6$  mm for LAD, respectively. There was no difference in the mean ectasia diameter measured by MRA and QCA ( $5.1 \pm 0.6$  vs.  $5.1 \pm 0.7$  mm,  $p$ : NS).

In the control subjects, the MRA measurements of the diameter of RCA and LAD were  $2.43 \pm 0.29$  and  $2.56 \pm 0.26$  mm. The QCA measurements were  $2.43 \pm 0.23$  and  $2.52 \pm 0.23$ , respectively.

In CAE patients, peak flow velocity was  $10.7 \pm 1.4$  cm/sec in RCA and  $11.4 \pm 2.3$  cm/sec in LAD. TFC was  $42.9 \pm 7.4$  in RCA and  $52.0 \pm 20.1$  in LAD. In the total CAE population, PFV was  $10.9 \pm 1.7$  cm/sec and TFC was  $45.9 \pm 13.1$ .

In controls, peak flow velocity was  $18.1 \pm 1.9$  in RCA and  $21.0 \pm 1.7$  cm/sec in LAD. TFC was  $20.4 \pm 1.59$  in RCA and  $19.8 \pm 1.12$  in LAD. Controls had significantly higher peak flow velocity ( $p < 0.001$ ) and lower TFC ( $p < 0.001$ ) in both RCA and LAD compared to patients with CAE (Fig. 2).

In patients with CAE, there was a negative correlation between PFV and TFC measurements ( $r = -0.74$ ,  $p < 0.001$ ) (Fig. 3). The ectasia diameter, measured by MRA, correlated negatively with PFV ( $r = -0.81$ ,  $p < 0.001$ ) and positively with TFC measurements ( $r = 0.77$ ,  $p < 0.001$ ).



**Figure 3.** Negative correlation between PFV and TIMI frame count (TFC).

#### 4. Discussion

According to the findings of the present study, coronary flow in patients with CAE measured as PFV by MRI is lower compared to controls and has a negative correlation with TFC measurements obtained by X-ray angiography. Additionally, PFV correlated negatively and TFC positively with the size of ectasia measured by MRA.

Patients with pure ectasia only were included in this study. Isolated coronary artery ectasia (CAE) is defined as the

excessive dilatation of a coronary artery without accompanying significant artery stenosis. Although the course of these patients is more benign than if obstructive coronary disease co-existed, thrombosis of the aneurysmal segments has been described (11).

CAE is characterized by slow flow and has been successfully described using invasive techniques (12, 22, 23). Slow flow has been advocated as the cause of myocardial ischemia and infarction without coincident significant coronary artery stenosis (4, 5). Although these techniques are very reliable, they have the disadvantage of being invasive and not easily repeatable for routine follow-up.

The TFC technique is a method for measuring coronary flow velocity from coronary angiograms. It correlates with Doppler guide-wire findings (19–21) and can be performed without lesion instrumentation. TFC has been previously used in the evaluation of CAE patients. Similar to our findings, patients with coronary ectasia had lower coronary flow velocity than either patients with obstructive coronary artery disease or controls (12).

Magnetic resonance angiography (MRA), a non-invasive technique that does not involve the use of ionizing radiation, has been proven to be of significant value in excluding three-vessel coronary artery disease (14). Our group and others have previously shown that MRA has a positive correlation with x-ray angiography, regarding the size of ectasia in CAE (24) and/or aneurysm in Kawasaki disease (25, 26). The results of the present study for the comparison between MRA and QCA are in agreement with these studies.

Quantitative flow measurement with MR phase contrast techniques (27, 28), has been well established and validated for larger vessels (29, 30). Several studies have dealt with the accuracy and reproducibility of flow measurements in coronaries and correlation with intra- and extra-vascular Doppler techniques (16, 17). Navigator measurements in small-caliber phantoms or coronary arteries in animals and humans (31, 32) have shown close correlation with corresponding measurements obtained through the use of MR techniques. Navigator techniques used in this study are based on rapid one-dimensional image acquisitions and accept image data only if the diaphragm position is within a previously defined range.

Compared with flow velocity measured by Doppler, there is a significant under-estimation of flow velocity measured by MR (16). This may be explained by several factors. Spatial resolution is low and therefore the determination of an average peak flow velocity within  $2 \times 2$  pixels covers a larger area than the fastest Doppler spectrum, used for the invasive measurements. Thus, slower areas are also included in the MR analysis. Temporal resolution is rather low and the time-point of peak flow may be missed with the MR examination, leading to further underestimation. This is, however, less pronounced with navigator technique, due to improvement of temporal resolution. Heart rate also may be slightly higher during the invasive procedure. Thus, flow is expected to be higher during the Doppler measurements.

The present study demonstrated that reduced PFV occurs in ectatic coronary vessels. This significant flow reduction may be particularly relevant to arterial thrombosis, resulting in myocardial infarction, even in patients without atherosclerotic lesions. The PFV measurements in our patients correlated negatively with the size of ectasia in agreement with previous studies using invasive techniques (12, 23).

The higher TFC measurements in our patients with CAE, indicative of slow flow, were in agreement with previous studies (12, 33). The correlation found between PFV, measured by MRI. TFC, measured by X-ray coronary angiography, is of importance since PFV has the advantage of being non-invasive and easily repeatable.

In the present study, there are some limitations. There is no measurement of Doppler guide-wire and direct comparison between PFV and TFC with Doppler results. However, our group have previously shown a good correlation between Doppler-wire and TFC measurements (21). A stress study, in order to calculate coronary flow reserve in these patients, was not performed.

Further validation in patients with concurrent obstructive lesions and prospective studies combining PFV measurements with clinical end-points will be necessary in order to establish the importance of these findings in treatment guidance and follow-up in patients with coronary ectasia. Study of flow with PFV gives functional information and offers an opportunity for stress protocol application in the future.

In conclusion, in this preliminary study slow flow was documented in patients with CAE, using MRI. The invasive TFC findings were found to correlate with the PFV measurements. The noninvasive nature of PFV gives the opportunity for serial, easily repeatable, flow evaluation in these patients.

## References

1. Seabra-Gomes R, Somerville J, Ross DN, Emanuel R, Parker DJ, Wong M. Congenital coronary artery aneurysms. *Br Heart J* 1974; 36:329–335.
2. Falsetti HL, Carroll RJ. Coronary artery aneurysm. *Chest* 1976; 69:630–636.
3. Swanton RH, Thomas ML, Coltarte DJ, Jenkins BS, Webb-Peploe MM, Williams BT. Coronary artery ectasia, a variant of occlusive coronary arteriosclerosis. *Br Heart J* 1978; 40:393–400.
4. Hartnell GG, Parnell BM, Pridie RB. Coronary artery ectasia, its prevalence and clinical significance in 4993 patients. *Br Heart J* 1985; 54:392–395.
5. Markis JE, Joffe CD, Cohn PF, Feen DJ, Herman MV, Gorlin R. Clinical significance of coronary artery ectasia. *Am J Cardiol* 1976; 37:217–222.
6. Oliveros RA, Falsetti HL, Carroll RJ, Heinle RA, Ryan GF. Arteriosclerotic coronary artery aneurysm. Report of five cases and a review of the literature. *Arch Intern Med* 1974; 134:1072–1076.
7. Swaye PS, Fisher LD, Litwin P, Vignola PA, Judkins MP, Kemp HG, Mudd GJ, Gosselin AJ. Aneurysmal coronary artery disease. *Circulation* 1983; 67:134–138.

8. Befeler B, Aranda JM, Embi A, Mullin FL, El-Sherif N, Lazzara R. Coronary artery aneurysms. Study of their etiology, clinical course and effect on left ventricular function and prognosis. *Am J Med* 1977; 62:597–607.
9. Al-Harhi SS, Nouh MS, Arafa M, Al-Nozha M. Aneurysmal dilatation of the coronary arteries: diagnostic patterns and clinical significance. *Int J Cardiol* 1991; 30:191–194.
10. Rab ST, Smith DW, Alimiurug BN, Rab R, King SB. Thrombolytic therapy in coronary ectasia and acute myocardial infarction. *Am Heart J* 1990; 119:955–957.
11. Rath S, Har-Zahav Y, Battler A, Agranat O, Rotstein Z, Rabinowitz B, Neufeld HN. Fate of nonobstructive aneurysmatic coronary artery disease: angiographic and clinical follow-up report. *Am Heart J* 1985; 109:785–791.
12. Papadakis M, Manginas A, Cotileas P, Demopoulos V, Voudris V, Pavlides G, Foussas S, Cokkinos D. Documentation of slow coronary flow by TIMI frame count in patients with coronary artery ectasia. *Am J Cardiol* 2001; 88:1030–1032.
13. Demopoulos V, Olympios C, Fakiolas C, Pissimissis E, Economides N, Adamopoulou E, Foussas S, Cokkinos D. The natural history of aneurysmal coronary artery disease. *Heart* 1997; 78:136–141.
14. Kim Y, Danias P, Stuber M, Flamm S, Plein S, Nagel E, Langerak S, Weber O, Pedersen E, Schmidt M, Botnar R, Manning W. Coronary magnetic resonance angiography for the detection of coronary stenoses. *N Engl J Med* 2001; 345:1863–1869.
15. Stuber M, Botnar RM, Danias PG, Sodickson DK, Kissinger KV, Van Cauteren M, De Becker J, Manning WJ. Double – oblique free-breathing high resolution three-dimensional coronary magnetic resonance angiography. *J Am Coll Cardiol* 1999; 34:524–531.
16. Nagel E, Bornstedt A, Hug J, Schnackenburg B, Wellnhofer E, Fleck E. Noninvasive determination of coronary blood flow velocity with MRI: comparison of breath-hold and navigator techniques with intravascular ultrasound. *Magn Reson Med* 1999; 41:544–549.
17. Nagel E, Thouet T, Klein C, Schalla S, Bornstedt A, Schnackenburg B, Hug J, Wellnhofer E, Fleck E. Noninvasive determination of coronary blood flow velocity with cardiovascular magnetic resonance in patients after stent deployment. *Circulation* 2003; 107:1738.
18. Hausleitert J, Nolte CWT, Jost S, Wiese B, Sturm M, Lichtlen PR. Comparison of different quantitative coronary analysis systems: ARTEK, CAAS, and CMS. *Catheter Cardiovasc Diagn* 1996; 37:14–22.
19. Gibson CM, Cannon CP, Daley WL, Dodge JT, Alexander B Jr, Marble SJ, McCabe CH, Raymond L, Fortin T, Poole WK, Braunwald E. The TIMI frame count, a quantitative method of assessing coronary artery flow. *Circulation* 1996; 93:879–888.
20. Dodge JT, Rizzo M, Nykiel M, Altman J, Hobkirk K, Brennan M, Gibson CM. Impact of injection rate on the thrombolysis in myocardial infarction (TIMI) trial frame count. *Am J Cardiol* 1998; 81:1268–1270.
21. Manginas A, Gatzov P, Chasikidis C, Voudris V, Pavlides G, Cokkinos DV. Estimation of coronary flow reserve using the thrombolysis in myocardial infarction (TIMI) frame count method. *Am J Cardiol* 1999; 83:1562–1565.
22. Kruger D, Stierle U, Herrmann G, Simon R, Sheikhzadeh A. Exercise-induced myocardial ischemia in isolated coronary artery ectasias and aneurysms (Dilated coronaropathy). *JACC* 1999; 34:1461–1470.
23. Hamaoka K, Onouchi Z, Kamiya Y, Sakata K. Evaluation of coronary flow velocity dynamics and flow reserve in patients with Kawasaki disease by means of a Doppler guide wire. *JACC* 1998; 31:833–840.
24. Mavrogeni S, Manginas A, Papadakis E, Foussas S, Douskou M, Baras P, Seimenis I, Cokkinos DV. Correlation between magnetic resonance angiography (MRA) and quantitative coronary angiography (QCA) in ectatic coronary vessels. *J Cardiovasc Magn Reson* 2004; 6:17–23.
25. Mavrogeni S, Papadopoulos G, Douskou M, Kaklis S, Seimenis I, Baras P, Nikolaidou P, Bakoula C, Karanasios E, Manginas A, Cokkinos DV. Magnetic resonance angiography is equivalent to x-ray coronary angiography for the evaluation of the coronary arteries in Kawasaki disease. *J Am Coll Cardiol* 2004; 43:649–652.
26. Greil G, Stuber M, Botnar R, Kissinger K, Geva T, Newburger JW, Manning WJ, Powell AJ. Coronary magnetic resonance angiography in adolescents and young with Kawasaki disease. *Circulation* 2002; 105:908–911.
27. Moran P. A flow velocity zeugmatographic interlace for NMR imaging in humans. *Magn Reson Imaging* 1982; 1:197–203.
28. Bryan DJ, Payne JA, Firmin DN, Longmore DB. Measurement of flow with NMR imaging using a gradient pulse and phase difference technique. *J Comput Assist Tomogr* 1984; 8:588–593.
29. Pelc NJ, Herfkens RJ, Shimakawa A, Enzmann DR. Phase contrast cine magnetic resonance imaging. *Magn Reson Q* 1991; 7:229–254.
30. Van Rossum AC, Sprenger M, Viser FC, Peels KH, Valk J, Roos JP. An in vivo validation of quantitative blood flow imaging in arteries and veins using magnetic resonance phase-shift techniques. *Eur Heart J* 1991; 12:117–126.
31. Mc Cauley TR, Pena CS, Holland CK, Price TB, Core JC. Validation of volume flow measurements with cine phase-contrast MR imaging for peripheral arterial waveforms. *J Magn Reson Imaging* 1995; 5:663–668.
32. Hoffman MB, Visser FC, van Rossum AC, Vink QM, Sprenger M, Westerhof N. In vivo validation of magnetic resonance blood volume flow measurements with limited spatial resolution in small vessels. *Magn Reson Med* 1995; 33:778–784.
33. Gulec S, Atmaca Y, Kilickap M, Akyurek O, Aras O, Oral D. Angiographic assessment of myocardial perfusion in patients with isolated coronary artery ectasia. *Am J Cardiol* 2003; 91:996–999.