Journal of Cardiovascular Magnetic Resonance (2006) **8,** 517–528

ISSN: 1097-6647 print / 1532-429X online
DOI: 10.1080/10976640600604963

Taylor & Francis
Taylor & Francis Group

PERIPHERAL ANGIOGRAPHY AND ATHEROSCLEROSIS

Peripheral MR Angiography

Hale Ersoy, HongLei Zhang, and Martin R. Prince

Weill Medical College of Cornell University, New York, NY, USA

ABSTRACT

Peripheral MR Angiography is rapidly developing and becoming the standard method for evaluating peripheral vascular disease. MRA allows accurate and detailed assessment of peripheral vasculature without requiring arterial catheterization, nephrotoxic contrast, or ionizing radiation. Latest improvements in this area include time-resolved MR angiography, stepping table bolus chase 3D MR angiography, fluoro-triggering, sub-systolic thigh compression to eliminate venous contamination, and parallel imaging. This article reviews these advances, describes how to use them effectively and how to avoid common pitfalls.

INTRODUCTION

In the last decade, peripheral MR angiography (MRA) has evolved into one of the most safe, rapid and accurate non-invasive diagnostic imaging methods for evaluating peripheral vascular disease (1–11). A comprehensive peripheral MRA protocol starts with time-resolved MRA of the symptomatic foot and calf using 6 to10 mL Gd followed by 2- or 3-station, 3D bolus chase MRA covering from diaphragm to ankles. This combines the benefits of high-resolution 3D imaging of the entire peripheral vasculature with additional time-resolved imaging of calf and foot arteries on the symptomatic extremity. Time-resolved MRA is helpful for assessing the adequacy of runoff, the significance of distal vessel disease and in addition provides valuable contrast arrival time information which is used for 3D bolus chase MRA timing.

Bolus chase 3D MRA is a multi-station examination in which a single contrast bolus is quickly imaged multiple times as it flows down the legs. The first station covers the abdominal aorta, its main branches, iliac and common femoral arteries. The second and third stations show arteries in the thigh and calf, respectively. Since atherosclerosis is a systemic disease, extension to whole body MRA is possible by adding stations to cover from the carotid arteries to the calf (12–20).

Keywords: Atherosclerosis, Angiography, MRA, Gadolinium, Spoiled Gradient echo, Tourniquet, Peripheral Vascular Disease.
Dr. Prince has patent agreements with Siemens, Philips, Topspins, Bracco, Epix, Berlex, Schering, Medrad and Mallinckrodt and a major stock holder of Topspins and Epix.
Received 8 August 2005; accepted 3 January 2006
Correspondence to:
Martin R. Prince
Weill Medical College of Cornell University
416 East 55th Street,
New York, NY 10022, USA
e-mail: map2008@med.cornell.edu

GENERAL CONSIDERATIONS

Equipment

Peripheral MRA is a demanding application that works best on state of the art magnets with the fastest possible gradient slew rate. Because of the need for large field of view (FOV) with a homogeneous field and signal reception, 1.5 Tesla systems with large FOV peripheral vascular coils are currently preferred. Once 3 Tesla systems are more optimized, 3T may become the preferred platform (15). However, dielectric effects, particularly in the region of proximal SFA, create non-uniform signal which may complicate image interpretation and prevents attaining the full signal to noise ratio (SNR) benefit.

Dedicated peripheral vascular surface coils provide higher SNR and contrast to noise ratio (CNR) compared to the body coil. This is particularly helpful for evaluating the small peripheral vessels. Thus, if a surface coil can be used for only one station, the best place for this coil is the calf station. Additionally, multi-channel phased array coils enable the use of parallel imaging techniques such as SENSE, iPAT or ASSET to further increase resolution.

Foam and straps for making the calf and feet motionless are critical since the legs and feet are highly mobile. Finally, two MR compatible blood pressure cuffs or tourniquets are needed

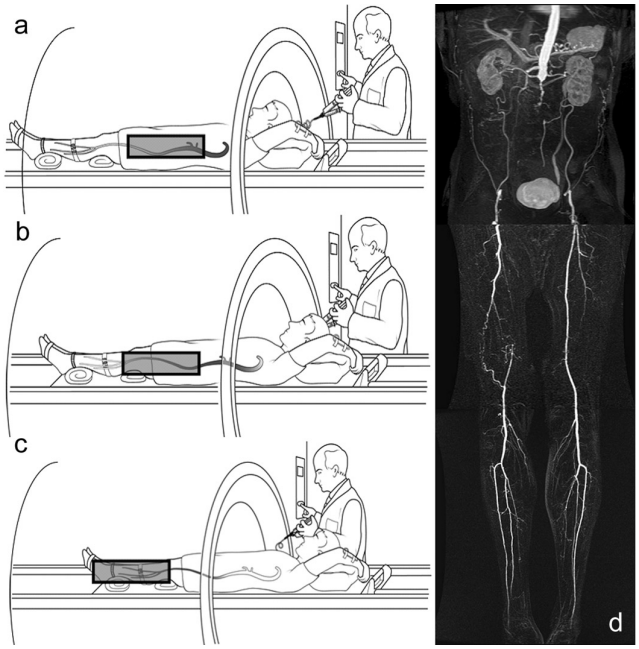

Figure 1. In bolus chase MRA, the MR scanner table moves in 3 steps (A, abdomen-pelvis, B, thighs, C, calves) to create a composite image of the (D) entire peripheral vasculature. Note the imaging volume overlaps at the levels of common femoral and popliteal arteries. Venous contamination was suppressed with sub-systolic thigh compression. Abdominal aorta is occluded just below the renal arteries (Leriche Syndrome); right superficial femoral artery is occluded at its origin and reconstituted at the adductor canal, widely patent popliteal arteries and three vessel run-off in both calves with diminutive posterior tibial arteries.

for applying sub-systolic compression to the thighs to prevent venous contamination.

Multi-station acquisition can be performed with either automated table motion or manual table translation using a set of positioning boards (2, 4, 5, 9) (Fig. 1). Automated moving table technology is available in newer generation MR scanners. The advantage of manual table motion over the automated table motion is the speed; instead of an interval of 5–7 s between the stations for automatic table motion, manual table translation requires only 2–3 s to move the table. Otherwise manual table motion is disadvantageous due to lack of reproducibility and precise positioning/registration. It is also only compatible with parallel imaging techniques that are auto-calibrating (e.g., GRAPPA). Continuous table motion has recently been introduced to eliminate time wasted for table motion. Some challenges related to this technique including motion correction artifacts, gradient warp effects, and table velocity adjustment to precisely chase the contrast bolus are under investigation (14, 21, 22).

When using manual table motion technique, the scanner is programmed to repeatedly acquire a single coronal 3D volume of MRA data as the patient is advanced through the imaging coil manually. Several companies have implemented a system for performing manual table motion this way including Angio-SURF (MR-Innovation, Essen, Germany) and SKIP (Magnetic Moments, LLC, Bloomfield, Hills, MI, USA). The coil assembly permits moving the patient through a single set of high SNR phased array coils (13, 23, 24).

Patient preparation

Intravenous (IV) access with a 20 or 22 gauge angiocatheter should be obtained before positioning the patient within the magnet bore to avoid patient position changing following pre-contrast mask acquisition (25). Securing the IV catheter with multiple pieces of tape is important to protect against pull out forces which may occur if the IV tubing gets caught while the table is moving in and out of the scanner during the study. Using a coiled tubing set designed for MR angiography, which recoils into a compact shape but can stretch out long enough to reach outside the magnet, minimizes this problem. After obtaining venous access (preferably in the right arm), the patient is placed supine on the scanner table typically with feet positioned to enter the magnet first. Large blood pressure cuffs are placed on each thigh as high as possible. The cuffs are not inflated until just before acquisition of the pre-contrast mask images to avoid the patient discomfort. However, the cuffs must be inflated before the mask image acquisitions because inflating the cuffs may change the leg position and lead to misregistration between mask and arterial phase images during subtraction.

In order to minimize motion artifact, it is useful to tape the feet together and pack them in foam. Ideally, the tape should not touch the skin, which may be fragile and sensitive in patients with peripheral vascular disease. Non-stick tape such as Kerlex can be used. The legs are horizontally extended and immobilized with foam cushions and stabilizing straps. Visco-elastic memory foam (3 to 4 inches thick) is particularly useful for maximum patient comfort as well as helping them to hold still during the study. Using this foam to elevate the calves improves alignment of the infra-popliteal trifurcation vessels with the abdominal aorta especially when this elevation is not provided by a peripheral vascular coil.

Contrast agent dose and injection rate

At present, the contrast agents used for routine clinical MRA are gadolinium (Gd) based with small chelators that allow redistribution into the extracellular fluid compartment. For MRA, these compounds are injected as a bolus and imaged during the arterial phase. The contrast agent dose for entire 3D run-off MRA is typically 0.3 mmol/kg. However, in order to simplify bolus timing, we prefer to use the same volume (45 mL) of contrast agent in all patients. Using the same dose and injection rate always produces the same bolus duration. Exceptions are made for patients weighing less than 50 kg (30 mL) or over 100 kg (60 mL).

The contrast agent injection rate must be fast enough to obtain sufficient arterial enhancement at three successive stations but slow enough to avoid excessive venous enhancement and to allow a long bolus for complete filling of the collaterals. Generally an injection rate of 1.5 mL/s is appropriate in most cases to provide a bolus at least 30 s with 45 mL of contrast agent. The contrast bolus is immediately followed by 20–30 mL saline

flush at the same injection rate in order to push the contrast agent through the superior vena cava.

Some investigators have advocated a split dose method in which the initial 20 mL of the contrast agent is injected at a rate of ~2 mL/s, and the remaining dose is injected at a lower rate, ~0.5–1 mL/s (26). This split dose method is thought to be useful when the scan time is too long for the blood flow rate (i.e., fast flow patients), so there is limited sharing of the bolus between the stations.

TIME-RESOLVED MR ANGIOGRAPHY OF THE FEET

Before performing bolus chase 3D MRA, it is useful, albeit optional, to perform a sagittal time-resolved MRA of the symptomatic distal calf and foot. Sagittal view of the pedal vasculature is particularly helpful for evaluating the vessels in this location. Time-resolved images also help to determine whether the patient has fast or slow flow as well as the time to venous enhancement. It can be performed by using a head coil, a long phased array coil, or the distal components of Total Imaging Matrix (TIM) for a larger FOV.

Time-resolved 2D and 3D MRA

Fast MR scanners can perform time-resolved imaging by repeatedly imaging the 3D volume of MRA data in rapid succession thereby capturing the contrast at multiple phases. The 3D acquisition can be as short as a few seconds by using a high bandwidth for short TR/TE, low flip angle (FA) of 15–20°, a small number of thick slices, and partial Fourier imaging. For example, at TR = 4 ms, a 24-slice volume with 256 × 160 matrix (160 × 24 = 3840 phase encode steps) can be acquired in 4 s with 2-fold parallel imaging and 50% partial Fourier imaging. Two dimensional projection MRA is even faster (27, 28). For feet, 5–8 s temporal resolution is acceptable. A higher temporal resolution may be useful in patients with pedal cellulitis or ulceration because these patients tend to have rapid arterio-venous transit time and thus early venous enhancement. In patients with claudication, slower (7–8 s) temporal resolution is more appropriate because a lower temporal resolution allows more time for higher spatial resolution (29). Vector subtraction of a pre-contrast mask dataset used with 2D projection MRA improves visualization of arteries that are smaller than the slice thickness (28).

Time-resolved imaging of contrast kinetics (TRICKS)

TRICKS is one of the refinements of key-hole imaging technique, in which the center of k-space is over-sampled while the periphery of k-space is under-sampled. Oversampling of the center of k-space improves the temporal resolution while minimizing reduction in spatial resolution (29–33). TRICKS allows a higher temporal resolution than what is possible with multiphase 3D MRA at the same spatial resolution. First, the system acquires a mask scan for automatic subtraction of background signal. Then, the 3D MRA is repeatedly imaged with the 3D gradient echo sequence, which samples the central k-space data every 5–8 s, referred to temporal resolution, during and after the injection of 10 mL Gd-based contrast agent at a rate of 1.5 mL/s. Temporal resolution can be adjusted by manipulating the number of slices, matrix (especially the phase encoding steps), phase FOV, bandwidth, and by utilizing the partial Fourier imaging.

The ideal imaging plane for feet is the sagittal plane. The symptomatic foot is imaged with a narrow (~ 6–8 cm) sagittal slab allowing high temporal and spatial resolution. It is also possible to cover both feet in a wider sagittal imaging volume of 15–20 cm by using more and thicker slices, albeit at the expense of both temporal and spatial resolution.

BOLUS CHASE 3D GD-MRA

Thigh compression

An important element of bolus chase 3D Gd-MRA is placement of blood pressure cuffs around the thighs as high up as possible toward the groin for venous compression (23, 34–36) (Fig. 2). Due to the conical shape of thighs, ordinary cuffs tend to slide down toward the knees and become loose. This problem can be overcome by using curved cuffs with a conical shape optimized for thigh compression (Smart Tourniquet, TopSpins Inc, Ann Arbor, MI, USA) (34). The blood pressure cuffs should be inflated just before obtaining the mask images and maintained at 50–60 mm Hg until the bolus chase MRA is completed. This is important for optimal image subtraction. Since the cuffs tend to leak, it may be necessary to give a few additional puffs during the study to maintain the pressure. Inflation of the cuffs after mask acquisition may change the leg position, thereby degrading the image quality after mask subtraction. In the patients with a femoral-popliteal graft, it is appropriate to keep the cuff pressure at 40 mm Hg due to the theoretical risk of graft thrombosis with excessive compression.

K-space ordering

Image contrast is determined by the center of k-space (8, 37). Therefore, the blood Gd concentration should be maximal in the

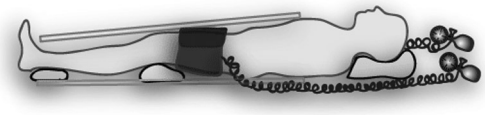

Figure 2. Dedicated peripheral vascular coil covers from mid-chest to ankles. The blood pressure cuffs are placed on both thighs and inflated to 60 mm Hg just before the 3D MR angiography mask image acquisition. The pressure should be at the same level during pre- and post-Gd acquisitions, and the cuffs should be deflated immediately after the arterial phase to avoid prolonged venous stasis.

region of interest during the acquisition of central k-space data. In the first station (abdomen-pelvis), sequential k-space ordering is the best in order to avoid early sampling of the k-space center. With sequential ordering, the sampling of k-space center occurs in the middle of acquisition. For the second (thigh) and the third (calf) stations, elliptical centric ordering is better in order to simplify bolus timing. When using elliptical centric ordering, the sampling of k-space center starts at the beginning of acquisition.

Prescribing coronal 3D volumes

Fast 2D time-of-flight (TOF) localizer pulse sequences take only 30–60 s per station and can be viewed as a lateral projection (e.g., MIP) for optimal positioning of the coronal 3D volume. The coronal 3D MRA slabs for each station can be prescribed with full FOV in order to maximize overlap (at least 3–5 cm) between stations (Fig. 3). Overlap at the common femoral bifurcation and the trifurcation regions provides images of these important regions at two different phases of the bolus, thus ensuring these areas are imaged adequately in at least one station.

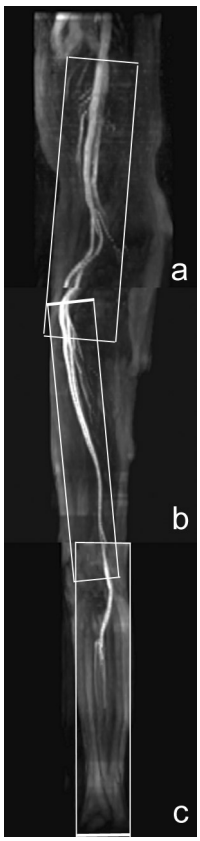

Figure 3. Sagittal reconstruction of axial time-of-flight localizer images of abdomen-pelvis (A), thigh (B) and calf (C) stations demonstrates the most anterior and posterior parts of the arterial tree. Coronal MR angiography slabs (shown as rectangles) are prescribed on these sagittal reconstructions. Note that when blood pressure cuffs are inflated, the thigh may raise a few cm. Accordingly, it is important to make sure there is sufficient room anterior to the superficial femoral artery to anticipate this change in position.

Table 1. Typical acquisition parameters for three-station 3D bolus chase MRA of peripheral arteries without parallel imaging

	Abdomen-pelvis	Thigh	Calf
TR (ms)	<10	<10	<10
TE (ms)*	<2	<3	<3
Flip angle	30	30	30
FOV (cm)	48	48	48
Slice thickness (mm)**	4	3–4	2–3
Number of slices**	30–40	20–30	30–40
Frequency encoding	512	512	512
Phase encoding**	~192	~192	~320
NEX	0.5–1	0.5–1	0.5–1
Phase FOV	0.8	0.7	0.7
K-space ordering	Sequential	Elliptical centric	Elliptical centric
Spatial resolution (mm^3)	$1 \times 2.5 \times 4 = 10$	$1 \times 2.5 \times 3 = 7.5$	$1 \times 1 \times 2 = 2$
Imaging time (seconds)	15–25	10–20	30–60

*If there are metal stents or clips, it is better to keep the TE shorter (<1 ms).
**Zero-filling should be utilized in slice direction (2-fold) and in the phase encoding direction (to achieve at least a 512 × 512 matrix after interpolation). If parallel imaging is available, the number of slices and phase encoding steps can be increased and the slice thickness can be decreased to enhance the spatial resolution and coverage.

In order to minimize the number and thickness of slices, the coronal volume can be prescribed slightly oblique on sagittal 2D TOF projection localizer images (Fig. 3). The number and thickness of the slices can be adjusted to obtain sufficient coverage with imaging times optimized to match the contrast bolus flow down the legs. Typical slice number and thicknesses used for each station are shown in Table 1. If necessary, one may use slices as thick as 4 mm with two-fold zero-filling resulting reconstructions overlapping 4 mm slices every 2 mm, or fewer phase-encode steps, i.e., 128 in the abdomen and thigh stations in order to shorten the scan times in patients with fast flow.

When utilizing a parallel imaging technique, larger imaging volumes, e.g., more slices, can be obtained without time penalty. When prescribing the 3D volumes for the thigh and calf stations, it is important to anticipate elevation of the distal thighs by 1 or 2 cm due to inflation of blood pressure cuffs.

Bolus timing

When using sequential k-space ordering, in order to synchronize the mid-point of the acquisition with the peak Gd concentration in the region of interest, there should be a time delay between the beginning of the injection and starting the acquisition. The time delay can be calculated by using the following

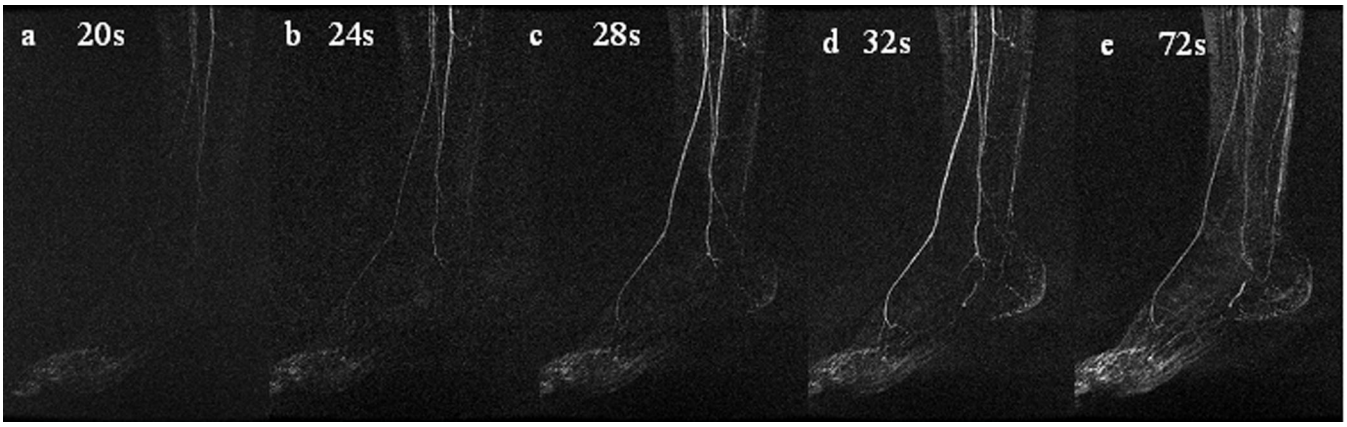

Figure 4. Time-resolved 2D projection MR angiography of the left foot following 6 mL Gd injection. A) 20 s, B) 24 s, C) 28 s, D) 32 s, E) 72 s. Time to fill distal station 24 s, time to fill pelvis 2/3 (24 s) = 16 s, time for venous contamination = 60 s. The foot is supplied by widely patent anterior and posterior tibial arteries.

equation:

$$\text{Scan Delay} = \text{Estimated Contrast Travel Time} + \text{Injection Time}/2 - \text{Scan Time}/2. \quad [1]$$

Of note, this equation only applies to a full k-space acquisition and must be adjusted when using partial Fourier imaging (e.g., 0.5 NEX) according to the manufacturer's recommendations. If the k-space is mapped centrically or elliptical centrically (38, 39), the equation is:

$$\text{Scan Delay} = \text{Contrast Travel Time} + \sim 6\ \text{s}. \quad [2]$$

The extra 6 seconds give time for Gd contrast concentration to peak and synchronize with acquisition of the k-space center, and it helps to avoid early initiation of central k-space data sampling during the rising leading edge of the bolus. The 6 seconds can be reduced if the absolute center of k-space is recessed or delayed in a few seconds from the beginning of the elliptical centric acquisition (40). It may also be made shorter for younger patients with faster flow or longer for older patients with slower flow.

When the contrast is injected into antecubital vein, estimated bolus arrival time to the abdominal aorta is about 15 s for a healthy young person, 20–25 s for individuals older than 70 years of age, 25–30 s for patients with heart failure or abdominal aortic aneurysm, and 40–50 s for patients with severe heart failure (41). If the injection site is at the hand, it is necessary to add 3–4 s to the estimated contrast arrival times.

Achieving good bolus timing for the thigh and calf stations is also challenging owing to the variations in blood flow rates and Gd arrival times (30, 41, 42). Contrast arrival time to the pedal arteries and venous enhancement can be determined from the time-resolved MRA acquisitions (Fig. 4). In an average patient, the time for contrast to arrive in the common femoral artery is 24 ± 6 s, with an additional 5 ± 2 s to reach the popliteal artery. Contrast bolus travels from the popliteal artery to the ankle in 7 ± 4 s. The total run-off travel time is about 36 s (41). If contrast travel time to the mid-calf is < 25 seconds, the patient has fast flow. If the time is > 30 seconds, the flow is considered slow. If venous enhancement is identified immediately after contrast arrival in the arteries, then the arterial phase window is exceedingly short. In some patients, time-resolved MRA in coronal plane or a large sagittal volume covering both legs may demonstrate an asymmetry in contrast arrival times between the legs (Fig. 5). In this case, the scan delay time should be adjusted according to the contrast arrival time in the symptomatic or slower flow side because it is better to image late than too early.

The recommended acquisition times for different patient populations are summarized in Table 2. Using fewer phase

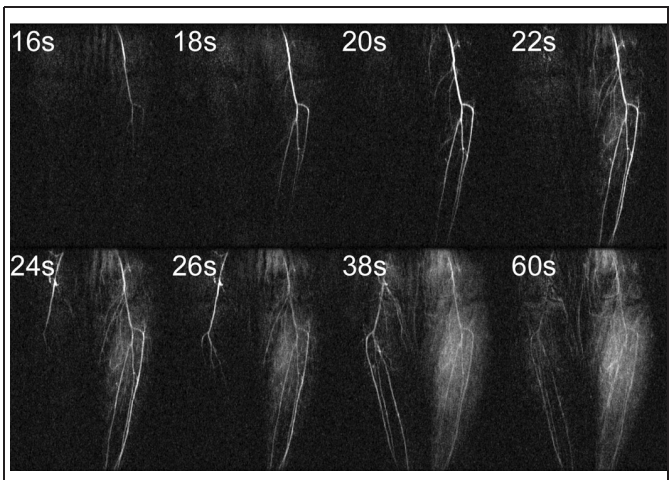

Figure 5. Coronal 2D time-resolved MRA images show asymmetrical contrast arrival in the calves with early enhancement of left calf soft tissue. If the symptomatic side is on the left, use a 2-station bolus chase (Table 2). If the right side is symptomatic, use a normal flow protocol may be better to allow adequate filling of right calf arteries. If both legs are symptomatic, put blood pressure cuff on only the left thigh and use the fast flow protocol.

Table 2. Bolus timing recommendations

	Contrast travel time to calf	Abdomen-pelvis	Thigh	Calf
Normal	25–30 s	20 s	~15 s	~50 s
Fast flow	<25 s	≤ 20 s	<15 s	~40 s
Slow flow	>30 s	25 s	20 s	~60 s
AV shunting*	variable	<15 s	<12 s	~30 s
		20 s	30 s	—

*AV shunting refers to very rapid transit of contrast agent from arteries to veins which occurs with cellulitis, ulceration, Charcot joints and AV malformations. These patients can be scanned very fast with three-station bolus chase MRA, or with a hybrid approach starting with time-resolved MRA of the calf followed by two-station bolus chase MRA with higher resolution.

encoding steps or fewer slices, utilizing parallel imaging, or prescribing partial phase FOV can accelerate data acquisition. Parallel imaging techniques (SENSE, ASSET, IPAT, GRAPPA, and SPEEDER) reduce the scan time by using multiple receiver coils in parallel, thereby accelerating data acquisition without requiring high gradient performance (43–46). Parallel imaging also compresses the center of k-space into a smaller duration, thus reduce the sensitivity to motion and bolus timing artifacts. However, a calibration scan that takes extra time and effort is required prior to the actual acquisition. It also introduces artifacts if the FOV is too small in the phase encoding direction, or if there is motion between the calibration scan and the actual MRA acquisition (referred to misregistration). In order to minimize misregistration, different techniques (e.g., GRAPPA) have been developed for interweaving a low resolution calibration scan into the actual scan, thereby concurrently acquiring the calibration scan and the actual scan.

Older patients (>80 years) and patients with heart failure or aortic aneurysm tend to have slow flow (time to calf >30 s) (41, 42, 47). In these patients, if data acquisition is too rapid, it is possible to get ahead of the bolus with incomplete filling of the thigh and calf arteries. Additionally, Gd arrival can be delayed in vessel segments distal to stenosis or occlusions. Therefore, it is recommended to prescribe a longer first station (up to 25 s). The second station can be lengthened up to 20 seconds with sequential k-space ordering instead of elliptical centric ordering. The third station can be 1 minute long with at least 512 × 512 resolution and should also be repeated to capture the arteries in the occasional patient with extraordinary slow flow.

Bolus timing is art more than science. The adjustments are based upon the experience of the operator and the assessment of flow rate for each individual patient. Fortunately, use of thigh compression provides a longer time window of arterial enhancement without venous contamination in the third station, so that bolus timing decisions are now less of an issue.

Fluoroscopic triggering

Fluoroscopic triggering technique is an alternative method for determining the contrast arrival into the abdominal aorta and eliminates the need for calculation of scan delay. This 2D projection MRA technique uses a gradient echo pulse sequence and produces 1–2 real time images per second (48–50). By watching these MR fluoroscopic images as they are reconstructed in real time, the operator can identify the leading edge of the contrast bolus arriving in the mid-aorta. However, in patients with slow flow or aortic aneurysm, waiting until the complete filling of the abdominal aorta is recommended to avoid ringing artifact. Initiating sequential data acquisition and breath holding within a few seconds of contrast arrival generally yields perfect arterial phase images of abdomen and pelvis (49, 51). It is helpful to include a portion of the lower chest during real time fluoroscopic MRI. This allows the operator to observe the passage of contrast media from pulmonary circulation to the left ventricle and then to the thoracic aorta. Observing the contrast approach into the proximal abdominal aorta provides confidence to the operator for anticipating the contrast arrival to the mid-aorta and helps to avoid false triggering of the actual 3D acquisition due to the inflow signal in the proximal abdominal aorta.

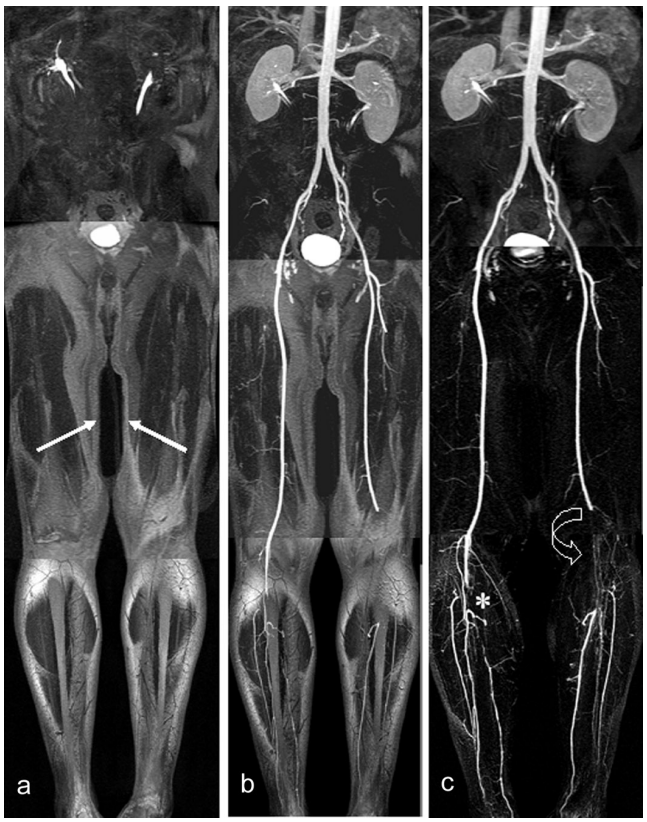

Figure 6. A) Pre-contrast coronal mask images, B) arterial-phase coronal Gd:MRA images, C); digital subtraction of the mask images from the post contrast images creates a DSA-like arteriogram. Note the indentations (arrows) of blood pressure cuffs inflated on the thighs. The mask image should always be checked for correct positioning and inflation of the cuffs before proceeding to the arterial phase. The popliteal artery is occluded on the left (curved arrow) with reconstitution of three runoff vessels. On the right side, the trifurcation is occluded (asterisk) with proximal reconstitution of three-vessel runoff.

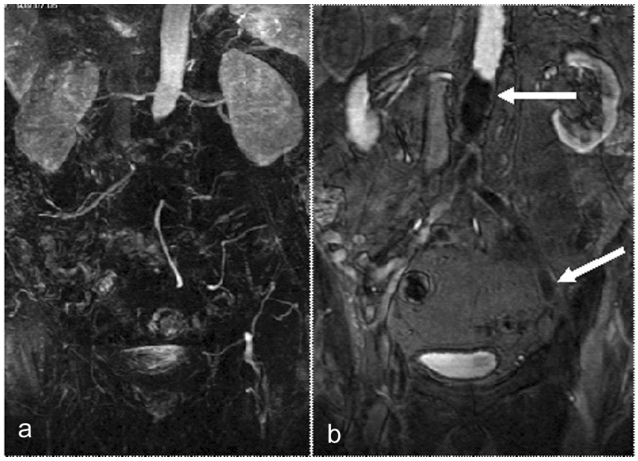

Figure 7. (A) 3D reconstruction of the source images demonstrates occlusion of the aorta just below the renal artery origins. Individual source image (B) shows an embolus to the aortic bifurcation and left iliac artery (arrows). Courtesy of James Meaney, MD.

Acquisition parameters

Spoiled gradient echo pulse sequence used for 3D Gd–MRA requires an echo time (TE) of <3 ms to minimize spin dephasing signal loss caused by turbulent flow or post-stenotic flow jets. Short TE also decreases the T2* effects, thus minimizes the metal and tissue-air interface susceptibility artifacts caused by metallic clips or stents, and bowel gas.

Repetition time (TR) should be as short as possible for fast acquisition. TR can be shortened by using a wider bandwidth, albeit with loss of SNR. This drawback can be balanced somewhat by increasing the Gd dose and injection rate, thereby increasing the Gd concentration in the arteries during central k-space acquisition.

FA can be in the range of 15°–45°. A lower FA is appropriate for lower Gd dose, lower injection rate and/or very short TR (e.g., <3 ms). For longer TR and higher dose/injection rate, a higher FA is preferred. High FA (∼60°) may be required in patients with metallic stents to overcome the radiofrequency shielding (Faraday Cage) effect of the stent. At 3 Tesla, SAR limitations will determine the FAs which should be as high as possible for the minimum TR (typically ∼20°).

Receiver bandwidth is another parameter that impacts TE, TR and SNR. Wider bandwidth allows shorter scan time at the expense of SNR. Narrower bandwidth increases SNR but also increases chemical shift and dephasing artifacts. However, chemical shift artifact can be eliminated with fat suppression. Most manufacturers have a fat suppression technique using a chemically selective inversion pulse that is applied only once per slice loop so as to minimize interference with water protons and to minimize the extra time required.

Zero-filling works by adding extra zeros to the k-space data array at the periphery before Fourier transformation. When the Fourier transformation is performed, zero-filling produces interpolated voxels or slices allowing smoother oblique reformations and maximum intensity projection (MIP) images. Typically, 3D MRA data is not isotropic because the slice thickness tends to be substantially greater than the in-plane voxel dimensions. Therefore, zero-filling in the slice direction reduces the angular "stairstep" artifact that occurs on the oblique reconstructions. Generally, 2-fold zero-filling in the slice direction

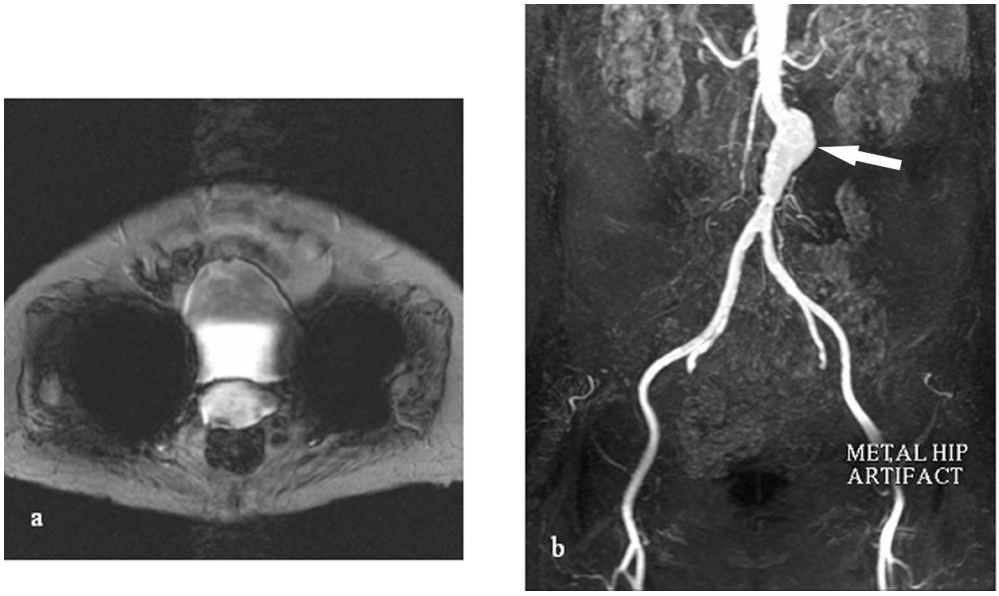

Figure 8. (A) Bilateral hip prostheses cause severe signal drop-out on axial 2D TOF image which has a relatively long echo time, ∼8 ms. (B) Gd-enhanced 3D MR angiography using a spoiled gradient echo sequence with a much shorter echo time, ∼1 ms, mostly eliminates the metal artifact, although there is still signal drop in the left common iliac artery under the "metal hip artifact" label. Also note 3 cm infrarenal abdominal aortic aneurysm (arrow).

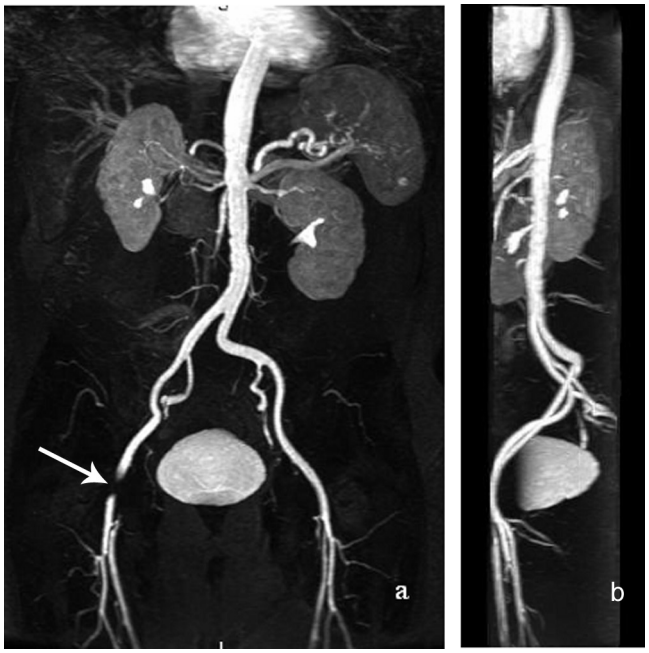

Figure 9. Coronal 3D MR angiography (A) shows segmental stenosis in the right common iliac artery (arrow). (B) The lateral view, however, indicates that this segment of the common iliac artery is outside the imaging volume creating a false image of arterial stenosis on the coronal MIP.

is mandatory to increase the number of the overlapping reconstructed images without sacrificing the SNR or lengthening scan time.

The acquisition time for each station is determined by the following equation:

$$\text{TR} \times \text{number of phase encode steps} \times \text{number of slices}/\text{SENSE factor}. \quad [3]$$

These parameters can be adjusted to achieve the optimal anatomic coverage and also scan time for sharing the contrast bolus between all three stations.

Post processing

Pre-contrast mask images acquired at all stations are subtracted from post-contrast source images to eliminate the remaining signals from fat and other stationary tissues. Subtraction creates DSA-like images (Fig. 6). However, if the inspiration level is not identical during pre and post-Gd image acquisition at the first station, or if there is leg motion during the second and third stations, the images obtained by subtraction may become worse than the source images. MIP images are 2D images generated from 3D data by using a ray tracing algorithm that displays the maximum pixel along each ray projecting through the 3D data. MIP thickness should cover the whole vessel thickness along its entire length or the segment of interest to avoid misinterpretation of an excluded part as a stenosis or occlusion. However, if the slice is too thick, overlapping background tissue signal or the other vessels included in the volume may obscure the region of interest and may lead to overestimation of stenosis. Standard views are AP and oblique MIPs of each station, sub-volume MIPs which are optimized for the aortic branch origins, bifurcations and the trifurcations.

Source images may show important intraluminal details that disappear on MIP images (Fig. 7). Therefore, analysis of the 3D data should always include reviewing the individual source images in addition to multi-planar, sub-volume MIPs and reformations of the source data.

PITFALLS

Metal artifact

Surgical metallic clips and intravascular stents can simulate a stenosis due to the signal dropout caused by susceptibility effects

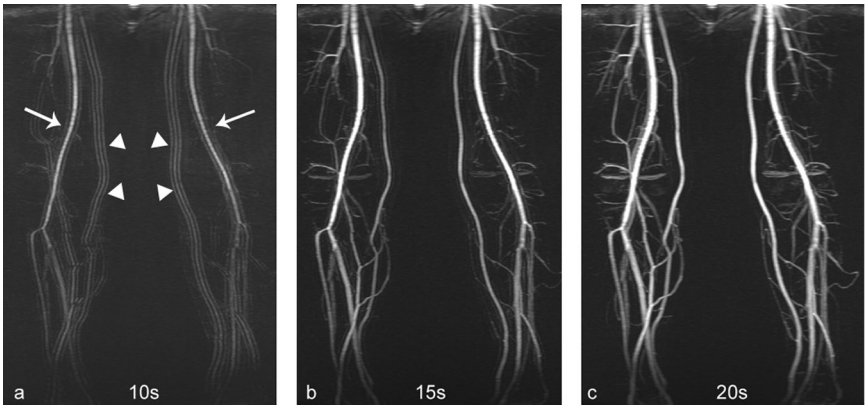

Figure 10. Ringing artifact in a 10-year-old patient referred to assess for vasculitis. (A) Early phase (10 s) of 3D TRICKS MR angiography demonstrates ringing artifact both in arteries (arrows) and veins (arrowheads) due to the early sampling of the center of k-space while the contrast bolus is still arriving. Venous filling is early due to the fast flow. On subsequent phases, (B) 15 s, and (C) 20 s, this ringing artifact disappears due to better synchronization of intravascular contrast peak with sampling of the k-space center.

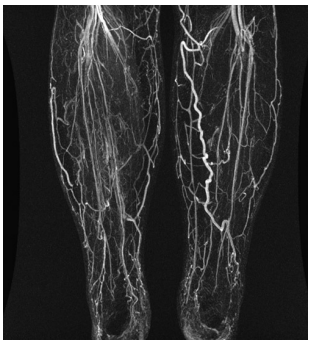

Figure 11. Coronal MIP from a 3D MRA of the calves. Delayed sampling of the k-space center causes extensive venous enhancement which obscures visualization of the arteries.

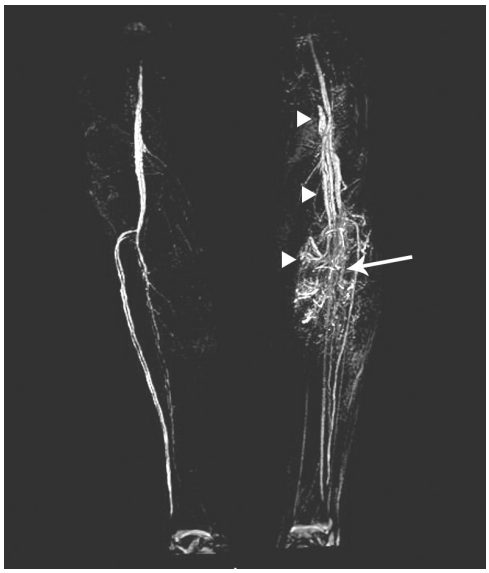

Figure 12. Coronal MIP shows arteriovenous fistula (arrow) in the left calf causing early venous filling (arrowheads) that obscures the arteries.

of the metals. Hip or knee prostheses can completely obscure the vessels (Fig. 8). Metal artifacts can be identified by a signal void accompanied by a characteristic bright signal build-up on one side of the signal void, which is not seen with a true stenosis or occlusion. Metal susceptibility can be minimized by using very short TE (<1 ms). This may be managed by utilizing a wide receiver bandwidth at the expense of SNR. TE can also be shortened by reducing the number of pixels in the frequency encoding directory by using fractional echo and/or by avoiding partial Fourier imaging.

The composition of stent is important for MR imaging. Nitinol, tantalum and platinum stents are non-magnetic and create fewer artifacts compared to ferromagnetic stents (52). The Faraday cage effect of the stent mesh attenuates the radiofrequency, signal and thus reduces the FA within the stent. This can be partially overcome by overflipping the spins with a larger FA (53). Using a 60 degrees FA in patients with non-magnetic stents may be helpful to visualize within the stent lumen.

Pseudo-occlusion

If the prescribed imaging volume does not cover the arterial anatomy entirely, the images may falsely resemble arterial obstruction (Fig. 9). Whenever a stenosis is seen in the common femoral artery, which is the most anterior segment, or in the common iliac or popliteal arteries which are the most posterior, it is important to check whether the 3D coronal imaging volume sufficiently covers these arteries or not. In order to avoid this problem, it is helpful to use a generous slab thickness with a comfortable margin to accommodate positioning errors of at least 1–2 cm. A useful method for aligning the infra-trifurcation vessel with the abdominal aorta is by placing either foam padding blankets or sheets underneath the calves.

Ringing artifact and venous contamination

For optimal SNR and CNR, the center of k-space should be acquired during the peak arterial Gd concentration. When

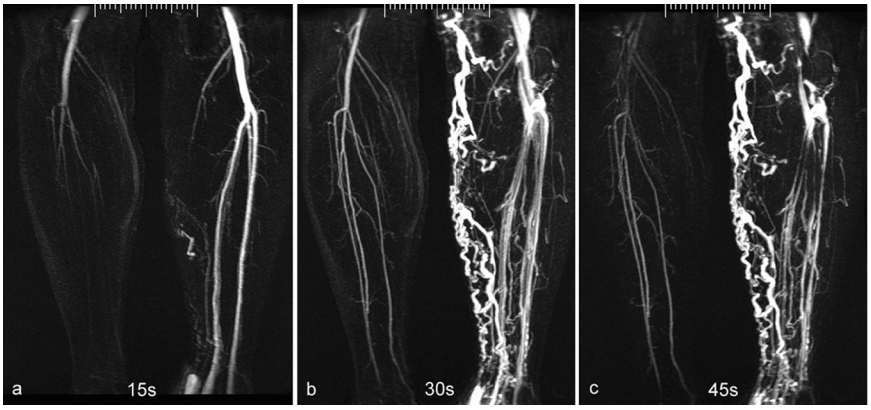

Figure 13. 3D MRA images of the calves following 20 mL Gd administration at (A) 15 s, (B) 30 s and (C) 45 s demonstrate rapidly enhancing prominent varicose veins in the left leg (Klippel-Trenaunay-Weber Syndrome).

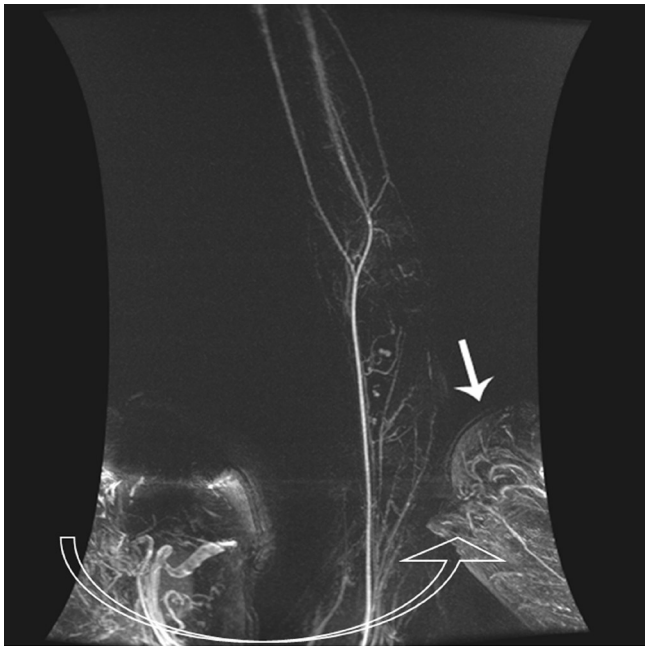

Figure 14. Contrast-enhanced 3D MRA of the arm was performed with the left arm raised above the head. Note the aliasing artifact from the head (arrow) that was partially included in the imaging volume.

the center of k-space data is acquired before the Gd concentration peaks in the region of interest, an edge ringing artifact occurs (54) (Fig. 10). If the center of k-space is acquired too late, venous and background enhancement may be excessive.

Even when the acquisition is timed well for the arterial phase, some patients have early venous filling (Fig. 11). Almost instantaneous venous filling occurs when there is an arteriovenous fistula (Fig. 12). Arteriovenous malformations may also cause rapid venous enhancement when the malformation is predominantly arterial (Fig. 13). Capillary and venous malformations are less likely to have venous contamination from early venous filling. Cellulitis and ulcerations also cause early venous enhancement. The best way to evaluate these patients is utilizing a time-resolved MRA technique with high temporal resolution ($\leq$ 6 seconds/frame).

Aliasing

Aliasing occurs when the FOV is narrower than the body part being imaged in the phase encode direction (Fig. 14). This rarely occurs with peripheral MRA using a 46–48 cm FOV unless it is prescribed highly rectangular. It is always useful to check the pre-contrast mask images for aliasing so that the FOV can be increased whenever necessary. Nevertheless, aliasing occurs on both mask and arterial phase images; thus, it can be eliminated by subtraction as long as there is no motion between the mask and post-contrast images. When using parallel imaging, aliasing is a more complex artifact and more difficult to remove after data acquisition. Thus, a sufficiently large FOV is critical for parallel imaging to completely avoid aliasing.

SUMMARY

Peripheral MRA has become a robust, reliable and accurate technique for evaluating peripheral vascular disease without risks of nephrotoxicity, arterial catheterization or ionizing radiation. An optimized protocol includes time-resolved imaging of the symptomatic calf/foot, two-or three-station 3D bolus chase MRA using fluoroscopic triggering for bolus timing, and subsystolic venous compression for longer arterial only imaging window. Multichannel phased array coils and parallel imaging contribute to further improvements in image spatial resolution and quality.

REFERENCES

1. Baum RA, Rutter CM, Sunshine JH, Blebea JS, Blebea J, Carpenter JP, Dickey KW, Quinn SF, Gomes AS, Grist TM. Multicenter trial to evaluate vascular magnetic resonance angiography of the lower extremity. American College of Radiology Rapid Technology Assessment Group. JAMA 1995; 274:875–80.
2. Earls JP, DeSena S, Bluemke DA. Gadolinium-enhanced three-dimensional MR angiography of the entire aorta and iliac arteries with dynamic manual table translation. Radiology 1998;209:844–9.
3. Foo T, Saranathan M, Prince M, Chenevert T. Automated detection of bolus arrival and initiation of data acquisition in fast, three-dimensional MR angiography. Radiology 1997;203:275–80.
4. Ho VB, Choyke PL, Foo TK, Hood MN, Miller DL, Czum JM, Aisen AM. Automated bolus chase peripheral angiography: Initial practical experiences and future directions of this work-in-progress. J Magn Reson Imaging 1999;10:376–88.
5. Ho KY, Leiner T, de Haan MW, Kessels AG, Kitslaar PJ, van Engelshoven JM. Peripheral vascular tree stenoses: Evaluation with moving-bed infusion-tracking MR angiography. Radiology 1998;206:683–92.
6. Keupp J, Aldefeld B, Bornert P. Continuously moving table SENSE imaging. Magn Reson Med 2005;53:217–20.
7. Meaney J, Ridgway J, Chakraverty S, Robertson I, Kessel D, Radjenovic A, Kouwenhoven M, Kassner A, Smith M. Stepping-table gadolinium-enhanced digital subtraction MR angiography of the aorta and lower extremity arteries: Preliminary experience. Radiology 1999;59–67.
8. Prince MR. Gadolinium-enhanced MR aortography. Radiology 1994;191:155–64.
9. Wang Y, Lee HM, Avakian R, Winchester PA, Khilnani NM, Trost D. Timing algorithm for bolus chase MR digital subtraction angiography. Magn Reson Med 1998;39:691–6.
10. Leiner T, Ho KY, Nelemans PJ, de Haan MW, van Engelshoven JM. Three-dimensional contrast-enhanced moving-bed infusion-tracking (MoBI-track) peripheral MR angiography with flexible choice of imaging parameters for each field of view. J Magn Reson Imaging 2000; 11:368–77.
11. Loewe C, Schoder M, Rand T, Hoffmann U, Sailer J, Kos T, Lammer J, Thurnher S. Peripheral vascular occlusive disease: Evaluation with contrast-enhanced moving-bed MR angiography versus digital subtraction angiography in 106 patients. AJR Am J Roentgenol 2002;179:1013–21.
12. Ruehm S, Goyen M, Barkhausen J, Kroger K, Bosk S, Ladd M, Debatin J. Rapid magnetic resonance angiography for detection of atherosclerosis. Lancet 2001;357:1086–91.

13. Ruehm S, Goyen M, Quick H, Schleputz M, Schleputz H, Bosk S, Barkhausen J, Ladd M, Debatin J. Whole-body MRA on a rolling table platform (AngioSURF). Rofo 2000;172:670–4.
14. Kruger DG, Riederer SJ, Grimm RC, Rossman PJ. Continuously moving table data acquisition method for long FOV contrast-enhanced MRA and whole-body MRI. Magn Reson Med 2002;47:224–31.
15. Leiner T, de Vries M, Hoogeveen R, Vasbinder GB, Lemaire E, van Engelshoven JM. Contrast-enhanced peripheral MR angiography at 3.0 Tesla: Initial experience with a whole-body scanner in healthy volunteers. J Magn Reson Imaging 2003;17:609–14.
16. Herborn C, Goyen M, Quick H, Bosk S, Massing S, Kroeger K, Stoesser D, Ruehm S, Debatin J. Whole-body 3D MR angiography of patients with peripheral arterial occlusive disease. AJR Am J Roentgenol 2004;182:1427–34.
17. Fain SB, Browning FJ, Polzin JA, Du J, Zhou Y, Block WF, Grist TM, Mistretta CA. Floating table isotropic projection (FLIPR) acquisition: A time-resolved 3D method for extended field-of-view MRI during continuous table motion. Magn Reson Med 2004;52:1093–02.
18. Ruehm SG, Goehde SC, Goyen M. Whole body MR angiography screening. Int J Cardiovasc Imaging 2004;20:587–91.
19. Goehde SC, Hunold P, Vogt FM, Ajaj W, Goyen M, Herborn CU, Forsting M, Debatin JF, Ruehm SG. Full-body cardiovascular and tumor MRI for early detection of disease: Feasibility and initial experience in 298 subjects. AJR Am J Roentgenol 2005;184:598–11.
20. Fenchel M, Requardt M, Tomaschko K, Kramer U, Stauder NI, Naegele T, Schlemmer HP, Claussen CD, Miller S. Receiving-channel MR system with surface coil technology: First clinical experience. J Magn Reson Imaging 2005;21:596–03.
21. Madhuranthakam AJ, Kruger DG, Riederer SJ, Glockner JF, Hu HH. Time-resolved 3D contrast-enhanced MRA of an extended FOV using continuous table motion. Magn Reson Med 2004;51:568–76.
22. Kruger D, Riederer S, Polzin J, Madhuranthakam A, Hu H, Glockner J. Dual-velocity continuously moving table acquisition for contrast-enhanced peripheral magnetic resonance angiography. Magn Reson Med 2005;53:110–17.
23. Herborn CU, Ajaj W, Goyen M, Massing S, Ruehm SG, Debatin JF. Peripheral vasculature: Whole-body MR angiography with midfemoral venous compression–initial experience. Radiology 2004;230:872–8.
24. Shetty AN, Bis KG, Duerinckx AJ, Narra VR. Lower extremity MR angiography: Universal retrofitting of high-field-strength systems with stepping kinematic imaging platforms initial experience. Radiology 2002;222:284–91.
25. Prince MR, Zhang HL, Dong Q, Ersoy H. A Primer for Dynamic MR Contrast Injection. Applied Radiology 2003;33:28–36.
26. Czum JM, Ho VB, Hood MN, Foo TK, Choyke PL. Bolus-chase peripheral 3D MRA using a dual-rate contrast media injection. J Magn Reson Imaging 2000;12:769–75.
27. Zhang HL, Khilnani NM, Prince MR, Winchester PA, Golia P, Veit P, Watts R, Wang Y. Diagnostic accuracy of time-resolved 2D projection MR angiography for symptomatic infrapopliteal arterial occlusive disease. AJR Am J Roentgenol 2005;184:938–47.
28. Wang Y, Johnston DL, Breen JF, Huston Jr, Jack CR, Julsrud PR, Kiely MJ, King BF, Riederer SL, Ehman RL. Dynamic MR digital subtraction angiography using contrast enhancement, fast data acquisition, and complex subtraction. Magn Reson Med 1996;36:551–6.
29. Van Hoe L, De Jaegere T, Bosmans H, Stockx L, Vanbeckevoort D, Oyen R, Fagard R, Marchal G. Breath-hold contrast-enhanced three-dimensional MR angiography of the abdomen: Time-resolved imaging versus single-phase imaging. Radiology 2000;214:149–56.
30. Hany TF, Carroll TJ, Omary RA, Esparza-Coss E, Korosec FR, Mistretta CA, Grist TM. Aorta and runoff vessels: Single-injection MR angiography with automated table movement compared with multiinjection time-resolved MR angiography–initial results. Radiology 2001;221:266–72.
31. Korosec FR, Frayne R, Grist TM, Mistretta CA. Time-resolved contrast-enhanced 3D MR angiography. Magn Reson Med 1996;36:345–51.
32. Schoenberg SO, Bock M, Knopp MV, Essig M, Laub G, Hawighorst H, Zuna I, Kallinowski F, van Kaick G. Renal arteries: Optimization of three-dimensional gadolinium-enhanced MR angiography with bolus-timing-independent fast multiphase acquisition in a single breath hold. Radiology 1999;211:667–79.
33. Swan JS, Carroll TJ, Kennell TW, Heisey DM, Korosec FR, Frayne R, Mistretta CA, Grist TM. Time-resolved three-dimensional contrast-enhanced MR angiography of the peripheral vessels. Radiology 2002;225:43–52.
34. Ersoy H, Keifer E, Zhang HL, Xu H, Prince MR. Curved thigh tourniquet for peripheral MR angiography. Presented at the 17th MRA Workshop. Beijing, China, September 20–24, 2005.
35. Bilecen D, Schulte AC, Bongartz G, Heidecker HG, Aschwanden M, Jager KA. Infragenual cuff-compression reduces venous contamination in contrast-enhanced MR angiography of the calf. J Magn Reson Imaging 2004;20:347–51.
36. Zhang HL, Ho BY, Chao M, Kent KC, Bush HL, Faries PL, Benvenisty AI, Prince MR. Decreased venous contamination on 3D gadolinium-enhanced bolus chase peripheral MR angiography using thigh compression. AJR Am J Roentgenol 2004;183:1041–7.
37. Maki JH, Chenevert TL, Prince MR. Contrast-enhanced MR angiography. Abdom Imaging 1996;23:469–84.
38. Wilman AH, Riederer SJ. Performance of an elliptical centric view order for signal enhancement and motion artifact suppression in breath-hold three-dimensional gradient echo imaging. Magn Reson Med 1997;38:793–02.
39. Fain S, Riederer S, Bernstein M, Huston Jr. Theoretical limits of spatial resolution in elliptical-centric contrast-enhanced 3D-MRA. Magn Reson Med 1999;42:1106–16.
40. Watts R, Wang Y, Redd B, Winchester PA, Kent KC, Bush HL, Prince MR. Recessed elliptical-centric view-ordering for contrast-enhanced 3D MR angiography of the carotid arteries. Magn Reson Med 2002;48:419–24.
41. Prince MR, Chabra SG, Watts R, Chen CZ, Winchester PA, Khilnani NM, Trost D, Bush HA, Kent KC, Wang Y. Contrast material travel times in patients undergoing peripheral MR angiography. Radiology 2002;224:55–61.
42. Wang Y, Chen CZ, Chabra SG, Winchester PA, Khilnani NM, Watts R, Bush HL, Jr., Craig Kent K, Prince MR. Bolus arterial-venous transit in the lower extremity and venous contamination in bolus chase three-dimensional magnetic resonance angiography. Invest Radiol 2002;37:458–63.
43. Sodickson DK, Manning WJ. Simultaneous acquisition of spatial harmonics (SMASH): Fast imaging with radiofrequency coil arrays. Magn Reson Med 1997;38:591–03.
44. Pruessmann KP, Weiger M, Scheidegger MB, Boesiger P. SENSE: Sensitivity encoding for fast MRI. Magn Reson Med 1999;42:952–62.
45. Blaimer M, Breuer F, Mueller M, Heidemann RM, Griswold MA, Jakob PM. SMASH, SENSE, PILS, GRAPPA: How to choose the optimal method. Top Magn Reson Imaging 2004;15:223–36.
46. Griswold MA, Jakob PM, Heidemann RM, Nittka M, Jellus V, Wang J, Kiefer B, Haase A. Generalized autocalibrating partially parallel acquisitions (GRAPPA). Magn Reson Med 2002;47:1202–10.
47. Zhang HL, Kent KC, Bush HL, Winchester PA, Watts R, Wang Y, Prince MR. Soft tissue enhancement on time-resolved peripheral magnetic resonance angiography. J Magn Reson Imaging 2004;19:590–97.
48. Luccichenti G, Cademartiri F, Ugolotti U, Marchesi G, Pavone P. Magnetic resonance angiography with elliptical ordering and

fluoroscopic triggering of the renal arteries. Radiol Med (Torino) 2003;105:42–7.

49. Riederer SJ, Bernstein MA, Breen JF, Busse RF, Ehman RL, Fain SB, Hulshizer TC, Iii JH, King BF, Kruger DG, Rossman PJ, Shah S. Three-dimensional contrast-enhanced MR angiography with real-time fluoroscopic triggering: Design specifications and technical reliability in 330 patient studies. Radiology 2000;215:584–93.

50. Butz B, Dorenbeck U, Borisch I, Zorger N, Lenhart M, Feuerbach S, Link J. High-resolution contrast-enhanced magnetic resonance angiography of the carotid arteries using fluoroscopic monitoring of contrast arrival: Diagnostic accuracy and interobserver variability. Acta Radiol 2004;45:164–70.

51. Wilman A, Riederer S, Huston J, Wald J, Debbins J. Arterial phase carotid and vertebral artery imaging in 3D contrast-enhanced MR angiography by combining fluoroscopic triggering with an elliptical centric acquisition order. Magn Reson Med 1998;40:24–35.

52. Wall A, Kugel H, Bachman R, Matuszewski L, Kramer S, Heindel W, Maintz D. 3.0 T vs. 1.5 T MR angiography: In vitro comparison of intravascular stent artifact. J Magn Reson Imaging 2005;22: 772–9.

53. Wang Y, Truong TN, Yen C, Bilecen D, Watts R, Trost DW, Prince MR. Quantitative evaluation of susceptibility and shielding effects of nitinol, platinum, cobalt-alloy, and stainless steel stents. Magn Reson Med 2003;49:972–6.

54. Maki J, Prince M, Londy F, Chenevert T. The effects of time varying intravascular signal intensity and k-space acquisition order on three-dimensional MR angiography image quality. J Magn Reson Imaging 1996;6:642–51.