Journal of Cardiovascular Magnetic Resonance (2006) **8,** 661–670

ISSN: 1097-6647 print / 1532-429X online
DOI: 10.1080/10976640600713814

Taylor & Francis
Taylor & Francis Group

CONGENITAL HEART DISEASE

Cardiac Magnetic Resonance of Single Ventricles

Mark A. Fogel, MD, F.A.C.C., F.A.A.P.

Division of Cardiology, Department of Pediatrics and the Department of Radiology
The Children's Hospital of Philadelphia, The University of Pennsylvania School of Medicine, Philadelphia, Pennsylvania, USA

INTRODUCTION

The assessment of the patient with a single ventricle is an enormous challenge to medical science. Not only are there are varied types of single ventricles, nearly all patients require either heart replacement or reconstructive surgery, including an aortic to pulmonary connection. During the various phases of reconstructive surgeries which eventually leads to the Fontan procedure (1), there are varying loads placed on the ventricle (from a volume loaded ventricle to a volume unloaded one) as well as varying physiologies, such as one from a run-off lesion into the pulmonary circulation (e.g., Norwood Stage I reconstrucion (2)) to one without one (final Fontan reconstruction).

Cardiac magnetic resonance (CMR) has come to play a major role in congenital heart disease, and the single ventricle is no exception (3). Because of the wide field of view and high resolution imaging of both 3-dimensional anatomy and physiology, CMR contributes to both the medical as well as surgical management in these patients. Since the single ventricle patient undergoes numerous surgeries (at least 2), the ability of CMR to detect myocardial scarring and regional wall motion abnormalities can aid in determining the etiology of poor ventricular performance. In conjunction with echocardiography, it can be used to avoid cardiac catheterization in many instances as patients progress through staged Fontan reconstruction (4).

This manuscript will discuss the role CMR plays in the care and management of the patient with the single ventricle. A brief background on staged Fontan reconstruction will be presented followed by the typical CMR scanning protocol in these patients. A few examples of the "wide world" of the single ventricle will then be shown. Finally, some studies of what CMR has contributed to what medical science now knows about the single ventricle will be discussed.

Received 2 August 2005; accepted 13 March 2006
Keywords: Single Ventricle, Magnetic Resonance Imaging, Pediatrics, Hypoplastic Left Heart Syndrome.
Correspondence to:
Mark A. Fogel, MD
The Children's Hospital of Philadelphia
Division of Cardiology
34th St. and Civic Center Blvd.
Philadelphia, PA 19104
tel.: 215-590-7566; fax: 215-590-5825
email: fogel@email.chop.edu

BACKGROUND

As suggested above, the anatomy of single ventricles are quite variable and include dividing this set of patients into categories such as: A) right (RV) vs left ventricle (LV), B) D-loop vs L-loop or C) true single ventricle (ie, an atrioventricular valve to ventricle connection where both atrioventricular valves or a common atrioventricular valve enters one ventricle in the presence of only one sinus portion of the heart) vs a "functional" single ventricle (any type of ventricular arrangement, such as a malaligned atrioventricular canal, where from a "functional" standpoint, the ventricle acts like a single pumping chamber). For example, a true single RV would be a heart that has both the mitral and tricuspid valves entering a single, morphologic RV chamber that gives rise to at least one great vessel whereas a "functional" single RV would be a patient who has hypoplastic left heart syndrome, where the mitral valve and left ventricle are too small to be usable. A true single LV, on the other hand, would be a heart that has both the mitral and tricuspid valves entering a single, morphologic LV chamber whereas a "functional" single LV would be a patient with tricuspid atresia, where the tricuspid valve is atretic and the RV is unusable. From this seemingly hopeless number of complex combinations is the unifying theme that only one usable ventricle is present or both ventricles are connected in such a way that separating them into 2 pumping chambers is impossible.

Figure 1 demonstrates, schematically, the physiology during all 3 stages of the single ventricle staged surgical reconstruction. Prior to any surgical intervention, in the patient's native state, if there is outflow obstruction or hypoplasia of one of the great vessels, blood flow to the obstructed circulation can be maintained by either flow in the ductus arteriosus (Figs. 1 and 2), flow through a stenotic pulmonary valve (allowing just enough blood to enter the pulmonary circulation) or flow through a ventricular septal defect if one or both great vessels arises from the hypoplastic ventricle. The goal of surgical reconstruction is to separate the

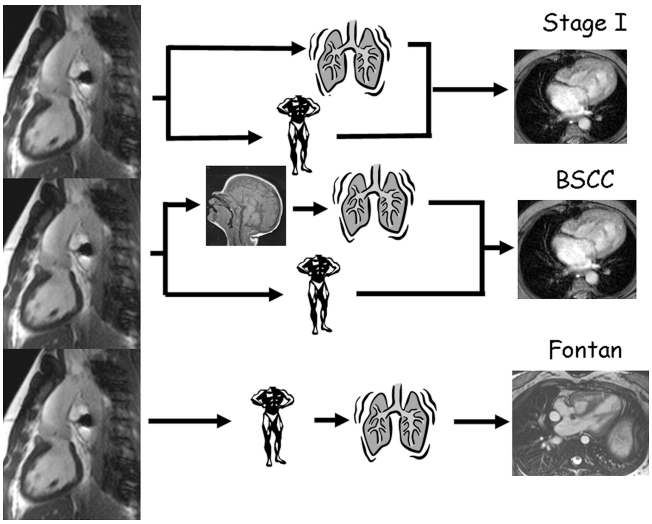

Figure 1. *Diagram of the different physiology at each stage of surgical reconstruction for single ventricles:* At Stage I, the single ventricle pumps to both systemic and pulmonary circulations in parallel with a systemic to pulmonary artery shunt (top). After bidirectional superior cavopulmonary connection (BSCC), the single ventricle pumps only to the systemic circulation with blood from the brain and upper body supplying flow to the lungs as well (middle). After Fontan reconstruction, the systemic and pulmonary circulations are in series (bottom).

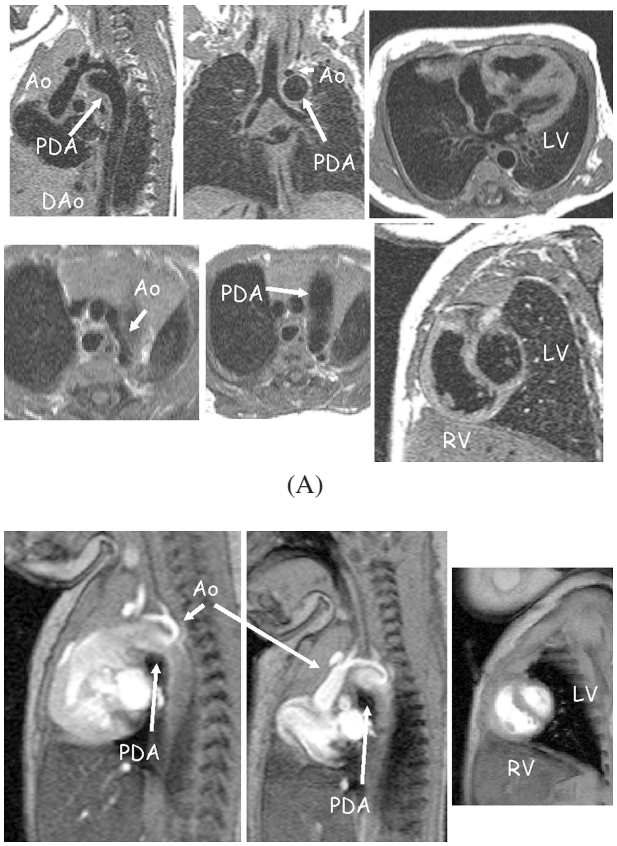

Figure 2. *Patient with hypoplastic left heart syndrome prior to Stage I.* (A) Double inversion dark blood images demonstrate the hypoplastic aorta (Ao) in long axis (upper and lower left) and the large patent ductus arteriosus (PDA) in long axis (upper left and lower middle). These structures are demonstrated in cross-section in the upper middle image. The upper and lower right images are again double inversion dark blood images which demonstrate the hypoplastic left ventricle (LV) in the 4-chamber and short axis views respectively. DAo = descending aorta. (B) FLASH images demonstrating the large PDA, flow in the hypoplastic Ao and the ventricles in short axis. RV = right ventricle.

systemic and pulmonary circulations by allowing passive blood flow into the pulmonary circulation while the functional single ventricle pumps to the systemic circulation. This type of surgical reconstruction is performed in stages and the physiology and loading conditions on the ventricle changes with each stage.

Prior to bidirectional superior cavopulmonary connection (BSCC), surgery may or may not be necessary (eg, tricuspid atresia, normally related great arteries and ventricular septal defect) if adequate but restricted pulmonary blood flow is present. Patients with hypoplastic left heart syndrome (Fig. 2), however, need immediate surgery–the Norwood Stage I procedure, which includes an atrial septectomy, a systemic to pulmonary artery shunt (Figs. 1 and 3) and an aortic to pulmonary anastomosis (Fig. 3). A right ventricular to pulmonary artery conduit (Sano procedure) has recently been substituted for the systemic to pulmonary artery shunt in some institutions (5). At this stage, the single ventricle pumps to both the systemic and pulmonary circulation in parallel, causing a volume overload.

Once pulmonary vascular resistance has dropped adequately (~4–6 months of age), the BSCC is performed, such as the hemiFontan procedure or the bidirectional Glenn (Fig. 4). This surgery is an anastomosis of the superior vena cava to the pulmonary artery with exclusion of this blood flow to the atrium and ligation of the systemic to pulmonary artery shunt. The ventricle does not pump directly to the pulmonary circulation in this physiology (blood needs to go through the head and arms first) and is therefore not volume loaded. It is not clear, however, that it remains volume unloaded throughout the time the patient is in this physiology (6). Cardiac output is maintained at the expense of cyanosis since only part of the systemic venous return enters the lungs (ie, flow from the head and arms and from aortopulmonary collaterals if present). This intermediate procedure was instituted when some studies noted that the ventricular wall thickness-to-chamber dimension ratio acutely increased when the Fontan procedure was performed without this step (6). Diastolic ventricular compliance issues were thought to play a major role in this as low output, tachycardia, and hemodynamic deterioration was present after the Fontan procedure. Another type of BSCC is one where an additional source of pulmonary blood flow is left in place, such as a systemic to pulmonary artery shunt or forward flow through a stenotic pulmonary valve. This physiology is definitely not volume unloaded.

At approximately 2 years of age, the Fontan operation is completed (Fig. 5) by directing inferior vena cava blood into the lungs by placement of a patch along the lateral wall of the

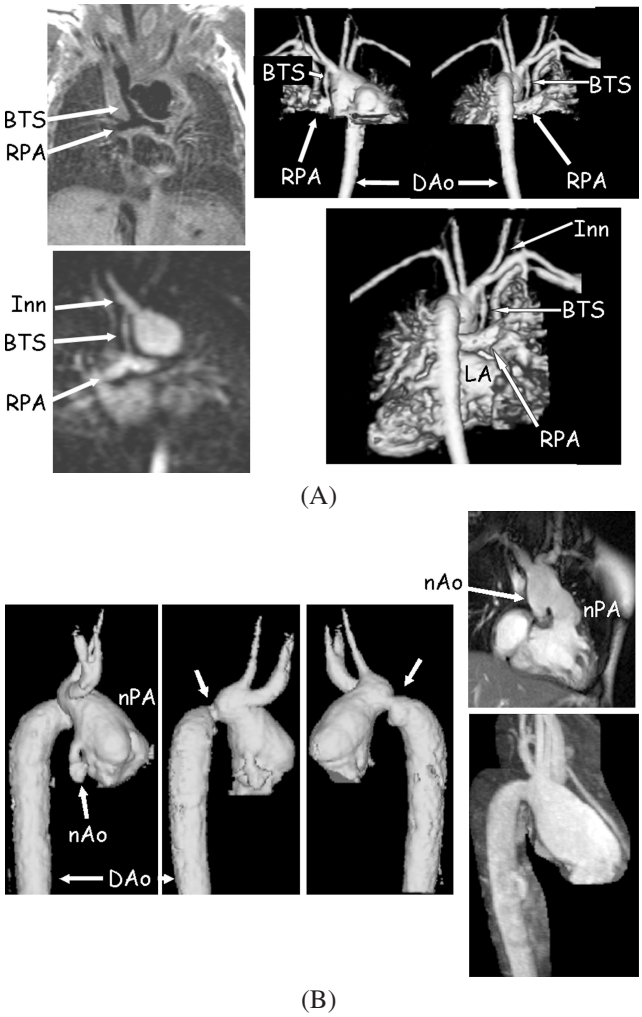

Figure 3. *Patient with single ventricle after Stage I.* Besides the atrial septectomy, the two main features of this operation is an aortic to pulmonary anastamosis and placement of a systemic to pulmonary artery shunt. (A) The upper and lower left images are off-axis coronal double inversion dark blood and gadolinium images of the right Blalock-Taussing shunt (BTS) from the innominate artery (Inn) connecting to the right pulmonary artery (RPA). The upper right two images are anterior and posterior views of a 3-dimensional shaded surface display of the aortic arch and a very medial BTS (with the heart removed). The lower right panel is a posterior view of that same patient with the heart in the image. DAo = descending aorta, LA = left atrium, LPA = left pulmonary artery. (B) The 3 leftward images are 3 different views of a shaded surface display of the aortic to pulmonary anastamosis and aortic reconstruction. The arrow points to an area of narrowing in the transverse arch. The BTS has been removed to visualize the arch better. The lower right image is a candy cane view of the same arch using a maximum intensity projection display. The upper right image is a still frame from a steady state free-precession image demonstrating the connection between the native aorta (nAo) and the native pulmonary artery (nPA).

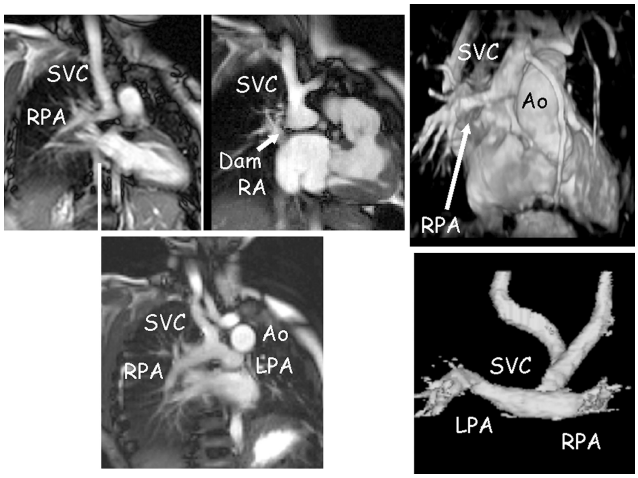

Figure 4. *Patient with single ventricle after superior cavopulmonary connection.* The left upper and lower images are steady state free precession images of 2 patients after a bidirectional Glenn where the superior vena cava (SVC) is divided from the right atrium (RA) and connected in an end-to-side fashion to the right pulmonary artery (RPA). The upper middle image is an off-axis view of a patient who underwent a hemiFontan, where the SVC is not divided surgically from the RA but instead, is connected side-to-side with the RPA and a "dam" is created surgically between the SVC and the RA, preventing blood from entering the RA from the SVC. The right upper image is an anterior view of a volume rendered 3-dimensional gadolinium dataset which also demonstrates the SVC-RPA connection and its relationship to the rest of the heart and great vessels (eg the aorta (Ao)). The right lower image is a shaded surface display isolating the SVC to RPA connection. LPA = left pulmonary artery.

atria ("lateral wall tunnel"), an extracardiac conduit, or utilizing an "atrio-pulmonary connection" (which is not performed anymore). With this, the circulations are now separated, and all blood must traverse the lungs by passive flow to maintain cardiac output. A "fenestration" is purposely created between the systemic and pulmonary venous pathways to allow for shunting between the circulations when there is increased pulmonary vascular resistance. The cardiac output can be maintained in this fashion at the expense of cyanosis. The fenestrations, in general, close on their own. Since the circulations are now separated, the ventricle is volume unloaded (after the fenestration closes).

For completeness sake, the reader should note that there is research underway to allow for one surgery in this process and to perform the rest of the manipulations using a catheter based approach. This is still considered experimental.

CMR PROTOCOL FOR IMAGING THE SINGLE VENTRICLE PATIENT

In general, the goal of CMR imaging in this patient population, as in any patient population, is to delineate the anatomy and assess the physiology and function to aid in medical/surgical management. As the single ventricle patient moves through staged reconstruction, the some of the specific targets of imaging change, but the overall goal remains the same. It goes without saying that each individual patient may have different needs and reasons for the CMR exam, and that takes precedence over other considerations. At all surgical stages (including pre-surgical), the following is the minimum assessment:

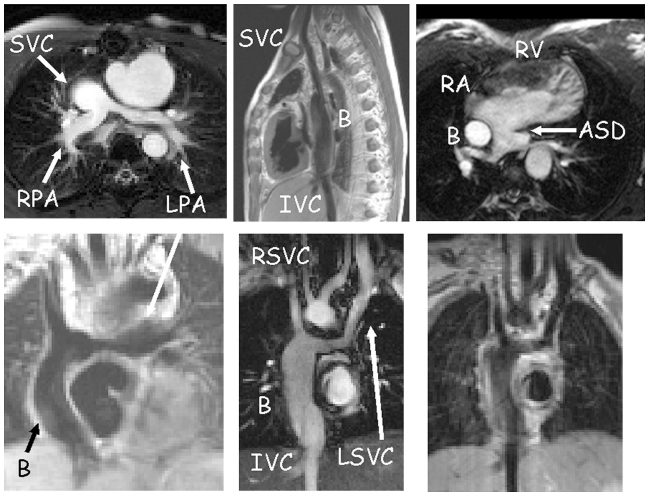

Figure 5. *The Fontan Connection.* All panels, with the exception of the middle and right lower ones, demonstrate a standard Fontan connection where a baffle (B) is placed between the inferior vena cava (IVC) and the superior vena cava (SVC)–right pulmonary artery (RPA) junction. The top left panel is an off-axis axial steady state free precession image of the SVC–RPA–left pulmonary artery (LPA) connection after Fontan. The upper middle and left lower panels are double inversion dark blood long axis views of the B in sagittal and coronal views respectively. The right upper panel is an off-axis 2-chamber view of a patient with a single right ventricle (RV) with the B shown in cross section at this level. The surgically created atrial septal defect (ASD) can easily be appreciated. The lower middle and lower right images, however, are of a patient with a bilateral bidirectional total cavopulmonary connection where the right (RSVC) and left superior vena cava (LSVC) are both connected to the ipsilateral branch pulmonary arteries and the baffle connects the IVC to the RSVC-RPA junction. RA = right atrium.

- aortic arch imaging, aimed mostly at patients with an aortic to pulmonary anastamosis, to assess for aortic arch obstruction (Fig. 3);
- pulmonary artery imaging, to assess for pulmonary artery stenosis, hypoplasia, or discontinuity (Figs. 3-5);
- anatomic assement of:
    1. the atrial septal defect (Fig. 5);
    2. ventricular outflow tract obstruction (especially in patients with a bulboventricular foramen);
    3. aortic-pulmonary collaterals;
    4. anomalous venous structures;
    5. pulmonary or systemic venous obstruction;
- ventricular function including regional wall motion abnormalities, ejection fraction, end-diastolic volume and mass, stroke volume, cardiac index and atrioventricular valve regurgitant fraction (see **Examples of Knowledge About Single Ventricles Gained From CMR Studies**);
- velocity mapping to assess for cardiac index, Qp/Qs, relative flows to both lungs and regurgitant fraction of the semilunar (and indirectly) atrioventricular valve.

At the presurgical stage, since much less is known about the patient's anatomy than at other stages, it is important to do an even greater detailed assessment of the anatomy. Anomalous venous structures, the presence of a left superior vena cava, delineation of visceral situs for heterotaxy, presence of an inferior vena cava, are all important issues to sort out. In addition, because some patients may be been resuscitated in the newborn period assessment of ventricular function and valve insufficiency is also extremely important to evaluate.

After the Norwood Stage I procedure, aortic arch imaging is important to evaluate the initial repair. Besides the aortic to pulmonary anastamosis and assessment of the distal aortic arch for obstruction, visualization of the aortic to pulmonary shunt (typically it is a right Blalock-Taussig shunt) is important (Fig. 3). This is generally done with dark blood imaging (or gadolinium) as the turbulence across this structure by cine generally causes signal loss. In the same vein, if an RV to pulmonary artery shunt was performed (ie, Sano procedure), this should be evaluated in the same fashion. Qp/Qs is obtained by velocity mapping in the ascending aorta (distal to the aortic to pulmonary anastamosis but proximal to the first aortic branch or if possible, at both semi-lunar values) and by either velocity mapping across the shunt or by velocity maps in each pulmonary artery using a high VENC (eg, 400 cm/sec) and as low a TE as possible. The status of the atrial septal defect should be assessed, and since this is a volume loaded stage, ventricular function is also a key imaging goal (Fig. 4).

After the BSCC (Fig. 4), imaging the superior vena cava to pulmonary artery anastomosis is the major difference with the Norwood Stage I patients. This can be evaluated with any one of numerous techniques including dark blood, cine or gadolinium sequences as the flows are generally low velocity. Qp/Qs utilizes flow in the superior vena cava or flow in both branch pulmonary arteries. If a hemiFontan was performed, imaging should assess whether any leak was present from the superior vena cava-pulmonary artery anastamosis into the atrium.

After the Fontan procedure, one of the most key structures to image is the entire systemic venous pathway for obstruction or clot (Fig. 5). Visualizing the fenestration flow (using cine) and assessment for thrombus in this structure are important points to determine. Since it is known that patients who have undergone the Fontan procedure have poor ventricular function (6), this form of imaging is an essential part of the exam. In addition, gadolinium enhanced imaging can help determine the presence of collaterals and to assess the aortic arch.

The conduct of the CMR scan, ideally, follows (after localizers):

1. A set of static steady state free precession contiguous axial images is used as a general survey of the cardiovascular anatomy and as subsequent localizers for other imaging in the scan. Obvious anatomic issues can be evaluated in this manner at the outset. In addition, if the scan is terminated early because of patient instability or technical problems, a full volume data set at least has been obtained and can be manipulated using multiplanar reconstruction to determine the salient points of the anatomy. One of the major drawbacks of this type of imaging is that if there is turbulence in structures during

diastole (eg, systemic to pulmonary artery shunt), signal loss and the inability to visualize the structure will occur. Systemic and pulmonary venous anatomy, the aorta and pulmonary arteries along with the size of the various cardiac chambers in diastole can be assessed at this point.

2. Our laboratory performs a set of contiguous HASTE axial images as simply another type of axial imaging while the imager loads the set of static steady state free precession contiguous axial images into multiplanar reconstruction for subsequent localizers.
3. Our lab utilizes multiplanar reconstruction of the axial images to a great degree, as mentioned, to localize subsequent imaging. This includes the candy cane view of the aortic arch (to assess for arch obstruction), long axis views of the pulmonary arteries, ventricular outflow tract and "2-chamber" long axis and short axis views of the heart for ventricular function. In addition, this is used to ensure image planes are perpendicular to flow for through plane phase encoded velocity mapping.
4. Double inversion dark blood imaging is used to evaluate for clot or masses in the systemic venous pathway of Fontan patients, to image the systemic to pulmonary artery shunt, or as an alternative to bright blood/cine CMR imaging of various important structures in single ventricles such as the size of the pulmonary arteries and evaluation of the aortic arch.
5. Cine CMR is next used to assess ventricular performance by obtaining cines of the "2-chamber" long axis and a set of contiguous short axis images from base to apex to quantitate end-diastolic volume, mass, ejection fraction, stroke volume and cardiac index of the single ventricle. Afterwards, if there are anatomic questions concerning certain structures, cines can be obtained of the pulmonary arteries (long axis, cavopulmonary anastamosis), the systemic and pulmonary venous pathways, the candy cane view of the aorta, the aortic to pulmonary anastamosis and ventricular outflow tracts.
6. Velocity maps are typically obtained across the aorta for cardiac output and across the branch pulmonary arteries for relative flows to both lungs. As checks to these, flow in the superior and inferior vena cavae and/or across the atrioventricular valve can be obtained. At the stage I, flow in the systemic to pulmonary artery or RV to pulmonary artery shunt can be obtained.
7. 3-dimensional gadolinium images are used for 3-dimensional imaging of the pulmonary arteries, aorta and systemic venous structures and lays the foundation for subsequent viability imaging 10–15 minutes later.
8. While waiting 10–15 minutes prior to viability images, special sequences or imaging are performed specific to the patient. If there are more anatomic questions, cines or static steady state free precession imaging can be used. Selected coronary imaging can be performed if there is a question, typically utilizing navigator sequences. Our lab generally performs myocardial tagging to further evaluate ventricular function at this part in the exam. Alternatively, some velocity mapping can be saved to this part of the exam to conserve time.
9. Viability is usually performed in the "2-chamber" long axis view and in the ventricular short axis view to evaluate for myocardial scarring. Since the single ventricle undergoes at least 2, if not more, operations with cardiopulmonary bypass and deep hypothermic circulatory arrest along with extensive intracardiac and extracardiac reconstruction, the possibility for myocardial scarring is always present. Viability sequences have also been used to identify patch material used for surgical reconstruction as well (7).

The above protocol typically can be performed in under an hour, and if the older Fontan patient can breathhold, in even less time.

Two other techniques worth mentioning to consider utilizing in the single ventricle patient is time-resolved 3-dimensional gadolinium sequences and "real-time" interactive steady state free precession cine CMR. Time-resolved 3-dimensional gadolinium can be used to assess not only anatomy very quickly but also physiology. For example, if there is a question of discontinuity between the branch pulmonary arteries as can happen in single ventricle reconstruction, following the gadolinium into the pulmonary arteries can detect whether a small connection exists between the branch pulmonary arteries. Our laboratory has used "real-time" interactive steady state free precession cine CMR after the static images are obtained to "sweep" through the heart and great vessels as is performed in echocardiography to quickly identify areas of concern, detect turbulence, etc. The subsequent higher resolution scans can target these regions for further assessment.

THE WIDE WIDE WORLD OF THE SINGLE VENTRICLE AND FONTANS

Figures 2–5 demonstrate the routine structures needed to be imaged throughout the course of staged Fontan reconstruction. Figure 2 shows images prior to any surgery, in this particular instance, a patient with hypoplastic left heart syndrome. Figure 3 demonstrates the systemic to pulmonary artery shunt and the aortic reconstruction of a patient who has underwent Stage I Norwood reconstruction.

Figure 4 shows the two most common forms of superior cavo pulmonary connections—the hemiFontan and the bidirectional Glenn procedures. These 2 procedures, which lead to the same physiology, are different. In the bidirectional Glenn, the superior vena cava is divided from the right atrium and connected in an end-to-side fashion to the right pulmonary artery while in the hemiFontan procedure, the superior vena cava is not divided surgically from the right atrium but instead is connected side-to-side with the right pulmonary artery and a "dam" is created surgically between the superior vena cava and the right atrium, preventing blood from entering the right atrium from the superior vena cava. The hemiFontan operation usually carries the patch

across the pulmonary artery to augment its size and has the theoretical advantage of setting up the patient to complete the Fontan in the cardiac catheterization laboratory with a covered stent.

Figure 5 shows examples of a standard Fontan completion (upper images and lower left), where the inferior vena cava is baffled to the pulmonary arteries. The routine repair generally has an extracardiac conduit or lateral wall tunnel placed in the right hemithorax or right atrium connecting the two structures. Axial, off-axis coronal and off-axis sagittal views using steady state free precession imaging generally can yield all the anatomic information needed, including visualizing the fenestration.

There are, however, a wide variety of anatomic variations of single ventricle lesions, and it is important that the CMR physician understands the anatomic, functional and physiologic nature of these as well as the creative repairs surgeons undertake to adequately assess these patients non-invasively with CMR. The lower middle and lower right images of Fig. 5 is an example of one such anatomic variation, a single ventricle patient with a right inferior vena cava and bilateral superior vena cavae. The patient underwent anastamosis of the superior vena cavae to the ipsilateral pulmonary artery as well as placement of a rightward inferior vena cava to right pulmonary artery anastamosis. This results in the "missing leg H" coronal view in the Figure.

Another approach when a left superior vena cava to coronary sinus is present is to connect the coronary sinus directly to the systemic venous pathway Fontan baffle instead of ligating and dividing the left superior vena cava and connecting it to the left pulmonary artery. Figure 6 demonstrates two functional results of this approach. The images on the left are 2 frames from a time-resolved 3-dimensional gadolinium injection showing this type of connection with a mildly dilated coronary sinus. The steady state free precession images in the middle and right are of a patient who was not as lucky and underwent massive dilation of the coronary sinus because of this physiology. The high right sided systemic venous pressures resulted in this coronary sinus expansion, and the patient had decreased ventricular performance, possibly due to coronary sinus hypertension, with decreased myocardial perfusion and/or mechanical impairment of the ventricle due to the coronary sinus dilation.

As medicine becomes more successful in the treatment of patients with congenital heart disease, an ever increasing number of children are living to adulthood. The physician imaging these patients not only has to be knowledgeable on the latest medical and surgical management, but also needs to be aware of surgical treatments which have preceded present day practice. One such sugery is the atrio-pulmonary connection for single ventricle reconstruction which is demonstrated in Fig. 7, which has fallen out of favor for the tunnel-like total cavo-pulmonary connection. The atrio-pulmonary Fontan, in its variety of forms, connects the atria directly to the pulmonary artery (usually using the atrial appendage). One of the major problems with this surgery was the marked dilation the atria undergoes afterwards, as is demonstrated in the Figure, with the subsequent risk of arrhythmia, thrombus formation and decreased cardiovascular

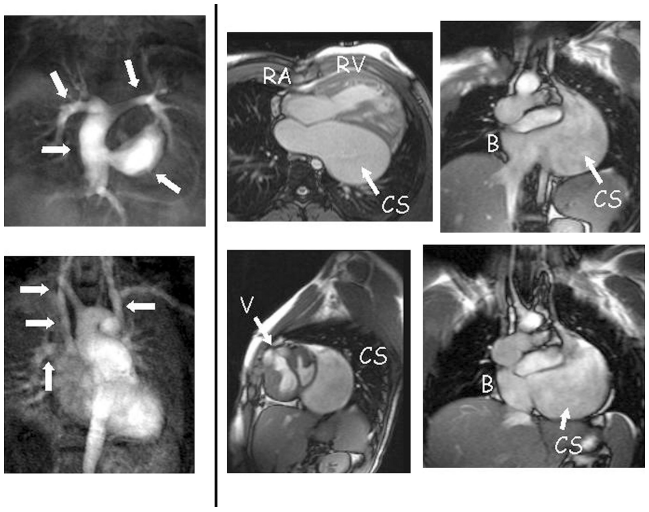

Figure 6. *The Left Superior Vena Cava to Coronary Sinus (CS) to Right Sided Baffle (B) Connection.* The left 2 panel are time resolved, 3-dimensional gadolinium injections demonstrating the anatomy. In the left upper panel, arrows point to the CS, the right sided Fontan B and the branch pulmonary arteries while on the lower left panel, arrows point to the left and right superior vena cavae (on "levophase") and the right pulmonary artery. The middle and right panels are steady state free precession images of a different patient with the same anatomy but with a severely dilated CS. The middle upper and middle lower panels are axial and ventricular (V) short axis views whereas the right most panels are 2 coronal views demonstrating this phenomenon. RA = right atrium, RV = right ventricle.

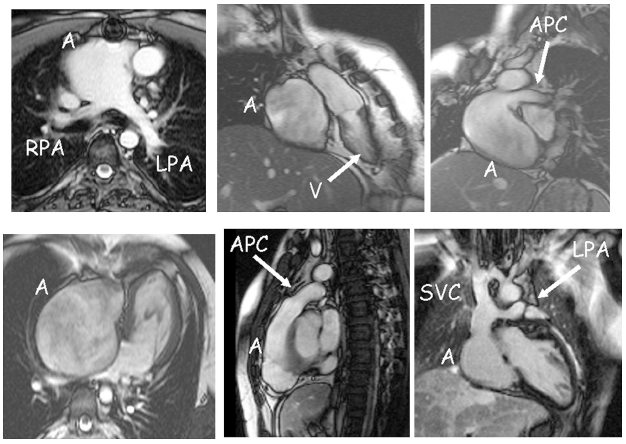

Figure 7. *The atriopulmonary (APC) Fontan Connection.* All panels are steady state free precession images of patients with tricuspid atresia. The left upper panels is an axial view of the connection between the atria (A) and the branch pulmonary arteries. The left lower and upper middle panel demonstrates one of the sequelae of this surgery which is severe dilation of the A. The middle lower and right upper panel demonstrates the APC in sagittal views in 2 different patients. The right lower panel demonstrates in the coronal view a patient who not only underwent an APC Fontan connection but also had a superior vena cava to pulmonary artery connection as well (Bjork modification to the APC Fontan). LPA = left pulmonary artery, RPA = right pulmonary artery, SVC = superior vena cava, V = ventricle.

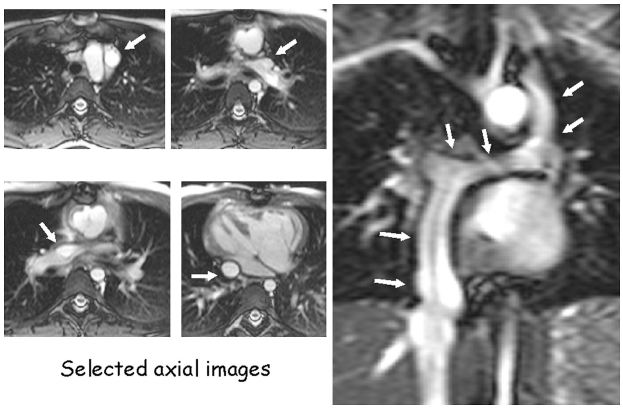

Figure 8. *The single, contralateral cavae Fontan Connection.* All panels are steady state free precession with the left and middle panels being selected axial images and the right panel being a coronal image demonstrating the anatomy. The selected axial images progress from superior to inferior as the panels go from upper left to upper middle to lower left to lower middle. A right superior vena cava is absent in this patient and only a left superior vena cava is present. The right inferior vena cava is baffled to the right pulmonary artery while the left superior vena cava is connected to the left pulmonary artery. The arrows outline this connection.

energetics and performance. The Figure also shows the Bjork modification to this procedure, where in addition to the atrio-pulmonary connection, there is a superior cavo-pulmonary connection as well.

Another anatomic variation is shown in Fig. 8. In this, a right inferior and left superior vena cavae are present with absence of the right superior vena cava. The repair is performed by connecting the left superior vena cava to the left pulmonary artery and baffling right inferior vena caval blood to the right pulmonary artery. This gives rise to the "zig-zag" coronal appearance to the systemic venous pathway seen in the Figure.

As a final example of the wide variety of anatomic connections an imager may encounter, Fig. 9 shows images of a patient with dextrocardia, a single left ventricle with a right ventricular outflow chamber and left sided juxtaposition of the atrial appendages with restrictive ventricular septal defects. The course of the systemic venous pathway is fairly complex. The conduit courses leftward and remaining posterior as it originates from the inferior vena cava, and once in the left hemithorax, courses anterior and superior along the left border of the heart. The conduit's anterior course takes it anterior to the pulmonary artery, where it finally takes a posterior course to insert anteriorly on this vessel. Figure 9 demonstrates the old saying that a picture is worth a thousand words (or in this case, at least 66 words).

Not only is there a wide variety of anatomic surgical connections, there is also a wide variety of morphologic single ventricles a CMR imager will likely come across. Figure 10 is just a small sample of the myriad of morphologic variations. Most fall into categories as mentioned in the beginning of this manuscript: A) RV vs LV, B) D-loop vs L-loop or C) true single ventricle vs a "functional" single ventricle. However, there are other morphologic variations which even complicates this,

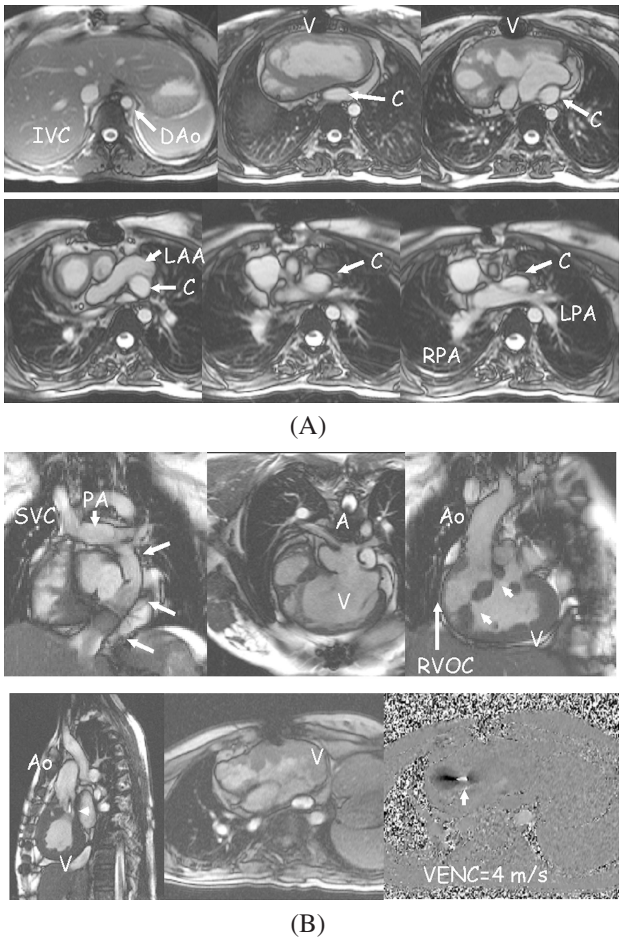

Figure 9. *The Curved Fontan Connection.* All panels are steady state free precession images (in A) of a patient with dextrocardia, single left ventricle (V) with a right ventricular outflow chamber (RVOC) and left sided juxtaposition of the atrial appendages. The ventricular septal defects are restrictive. (A) Selected axial images which progress from inferior to superior as the panels go from left to right (top more inferior than bottom images). The Fontan conduit (C) proximally connects to the right sided inferior vena cava (IVC) and as it progresses distally, courses to the left hemithorax posteriorly. It then courses superiorly and anteriorly on the left side to insert anteriorly into the left pulmonary artery (LPA). (B) The upper left panel is a coronal view of the entire extent of the baffle in one image (arrows) connecting to the pulmonary artery (PA). The upper middle panel is an off-axis 2 chamber view of the main pumping V. The upper right image is a coronal view demonstrating the anatomy with one single left V pumping chamber and the RVOC with restrictive ventricular septal defects (arrows). The only outlet to the single left V is through these ventricular septal defects. The lower left and middle panels are 2 views through the restrictive ventricular septal defects; note the abnormal jet visualized on the lower left image (arrowhead). The lower right panel is an in-plane phase encoded velocity map through this region at a velocity encoding of 400 cm/s with increased signal intensity indicating the blood flow exceeded this value.

such as dextrocardia vs levocardia, supero-inferior ventricles, criss-cross atrioventricular relations, atrioventricular canal vs 2 separate atrioventricular valves, etc. The Figure shows examples from each one of these categories.

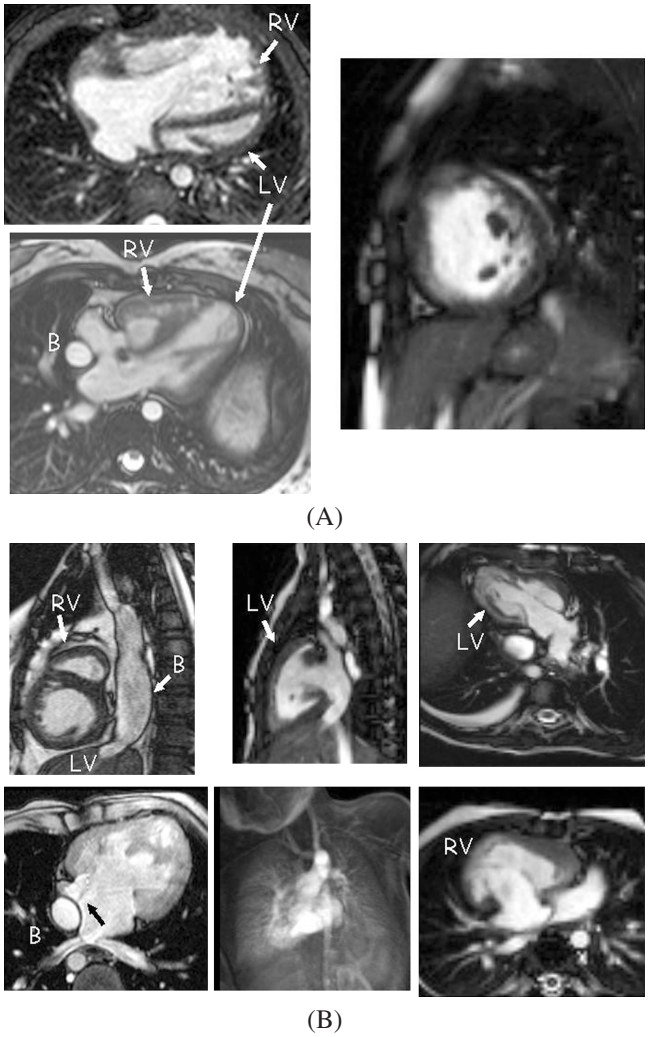

Figure 10. *Various Forms of Single Ventricles.* (A) Two common forms of single ventricles are hypoplastic left heart syndrome (upper left image) and pulmonary atresia with tricuspid stenosis and hypoplastic right ventricle (RV) (lower left image). The former represents a "single RV" and the latter represents a "single left ventricle (LV)" form of single ventricle. The right image is a short axis view of a patient with a single LV. **(B)** Examples of more complex single ventricle lesions include patients with supero-inferior ventricles (upper left panel). The systemic venous return enters the atria which connects to the inferior morphologic LV (upper middle and upper right images) while the pulmonary venous return enters the atria which connect to the superior morphologic RV (lower right panel). The patient has obvious dextrocardia. Time resolved 3-dimensional gadolinium injection demonstrates this as well along with pulmonary lung perfusion (lower middle panel). The lower left panel is an example of a patient with a malaligned atrioventricular canal resulting in a single RV which underwent Fontan reconstruction. Flow across the fenestration can be seen (black arrow). B = baffle.

The examples in this section is just a sampling of the wide variety of surgical reconstructions and morphologic single ventricle the CMR imager may come across. It is impossible to "memorize" all of them; however, if the CMR imager is schooled in basic principles of congenital heart disease as well CMR principles, the anatomic, physiologic, functional and surgical assessment of the single ventricle patient utilizing CMR can be performed successfully.

EXAMPLES OF KNOWLEDGE ABOUT SINGLE VENTRICLES GAINED FROM CMR STUDIES

As with the previous section, it would be impossible to outline all that CMR has contributed to our understanding of congenital heart disease. The examples to follow are just a taste of what has been learned and sheds some light on the potential of CMR in the future to elucidate anatomy, physiology and function in congenital heart disease to improve patient care.

Flow

A perennial question always concerns the driving force behind "passive" lung flow in single ventricle patients. It appears to be a combination of negative intrathoracic pressure during inspiration and, either directly or indirectly, the systemic ventricle's contraction and motion (8–12). The amount to which all these factors contribute to this passive flow remains debatable with reports of either atrial contraction, ventricular systole, ventricular diastole or the respiratory component determining this flow.

It is clear that dependence of pulmonary blood flow in Fontan physiology cannot be wholly based on respiration because a Fontan patient on a respirator receiving positive pressure ventilation would not survive. It is also clearly not wholly cardiac dependent. In a cardiac MRI study using bolus tagging (8), flow in the Fontan baffle was imaged both gated to the respiratory cycle using bellows at end-inspiration and end-expiration and triggered to the cardiac cycle via ECG. If flow was soley respiratory controlled, then an ECG triggered study would demonstrate similar images at all cardiac phases. If flow was soley cardiac controlled, then a respiratory gated study would demonstrate similar images at end-inspiration and end-expiration. Both types of scans demonstrated different images during the cardiac cycle and the respiratory cycle. Because cardiac and respiratory cycles occur simultaneously, flow dependency in this study was defined as the percent change in flow during imaging triggered to the cardiac cycle (or gated to the respiratory cycle) as a fraction of the sum of flow changes noted during ***both*** cardiac triggering and respiratory gating. Using this definition, nearly 70% of flow was cardiac dependent, with the rest of the flow being respiratory dependent. Maximum flow occurred during late systole-early diastole (2nd quarter of the cardiac cycle) with the slowest flow occurred during diastasis in the 3rd quarter of the cardiac cycle.

This flow appears to be fairly complex. In a recent article published by Zelicourt et al. (13), CMR anatomic data was used to create a model using transparent stereolithography. Power loss, digital particle velocimetry and flow visualization revealed complex, unsteady and a highly 3-dimensional flow structure with high pressure drops and power losses. Most of the dissipation of the energy occurred in the pulmonary arteries.

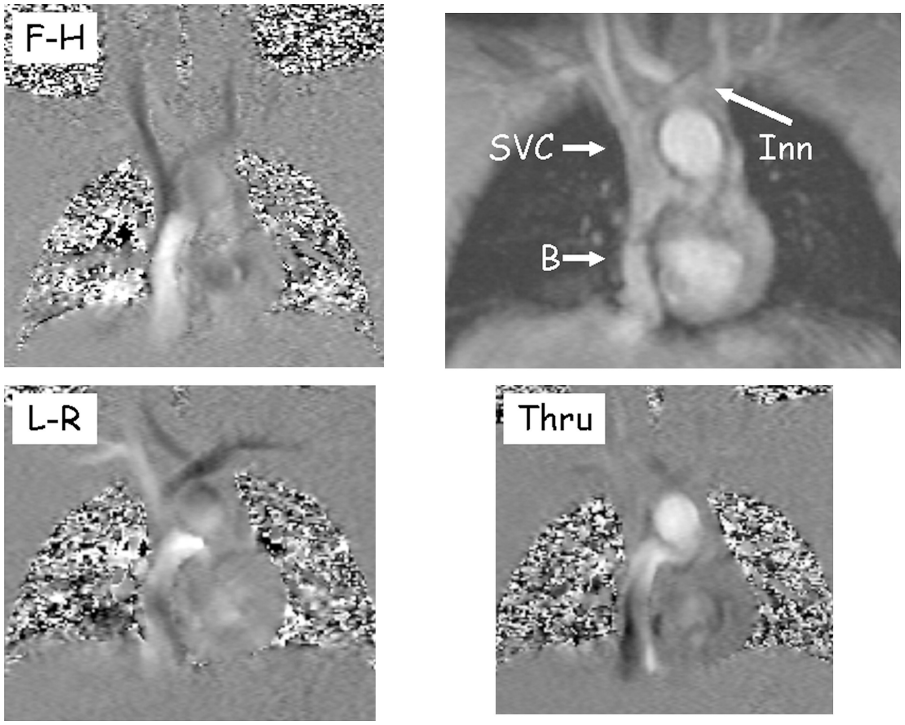

Figure 11. *3-plane velocity mapping in the systemic venous pathway of a Fontan patient.* The upper right amplitude image depicts the anatomy of the Fontan baffle (B). The upper left, lower left and lower right are velocity maps encoded foot-head (F-H), left-right (L-R) and through plane (Thru) of the baffle respectively. F-H, L-R and Thru encodes increased bright signal intensity toward the head, left and posterior respectively. Note the flow patterns.

Many of the studies utilizing mathematical models and flow optimization in Fontan patients rely on the knowledge of the caval contribution of flow to each lung, to systemic venous return and the relative flow to each lung. Using presaturation tagging to "label" blood from each cava, a CMR study was performed on 10 single ventricle patients with lateral wall tunnel Fontans to determine just those parameters, published in 1999 (14). Sixty percent of superior vena caval blood was found to flow into the right pulmonary artery, and 67% of inferior vena caval blood flowed towards left pulmonary artery (ie, superior vena caval blood was directed to the right pulmonary artery and inferior vena cava blood was directed towards left pulmonary). The inferior vena cava contributed 40% to total systemic venous return in these approximately 2-year-olds, and the distribution of blood to each lung was nearly equal. Three-plane velocity mapping is also an extremely valuable tool in visualizing and analyzing these flows (Fig. 11), although it can't "label" blood from each cava.

Ventricular function

The total heart volume concept (ie, that the combined volume of both atria and ventricles does not change during the cardiac cycle) is a measure of the integrated function of the heart, the change is as little as 5% (15). This occurs by reciprocating volume changes in the atria and ventricles during the cardiac cycle and results in minimizing the energy needed in moving extracardiac structures. The same is true for intracycle constancy of the center of mass motion for that exact reason (16, 17). In a 1993 study (17), CMR demonstrated that 4/10 patients prior to hemiFontan had total heart volumes vary by >5%, and the center of mass of the entire heart significantly moved in the antero-posterior and supero-inferior planes. Seventy-one percent of Fontan patients also did not have constant total heart volume, and although not volume loaded, it is presumed that this law was disrupted in part by baffle placement. When the heart's center of mass motion was broken down into orthogonal components, correlations existed between the lateral plane and the anteroposterior and superoinferior planes ($r^2 = 0.51$–0.91), presumably because these planes are linked by the lateral wall tunnel baffle sewn into the lateral and posterior walls of the atria. These findings indicated that the volume loaded single ventricle not only performs more volume work but also "wastes" energy by unnecessarily displacing extracardiac structures, in the Fontan group of patients along with patients prior to hemiFontan reconstruction. Only 1/8 patients (13%) after hemiFontan (but prior to Fontan) exceeded the 5% limit of total volume change throughout the cardiac cycle, and the hemiFontan group has the least center of mass motion than the other 2 surgical subgroups.

As the single ventricle patient progresses through staged surgical reconstruction, different physiological stresses are placed on the ventricle which in theory, should lead to altered regional

strain and wall motion. When this was studied myocardial tagging using CMR (18), the highest regional compressive strains were found to occur in the ventricles prior to the hemiFontan procedure and in those after the Fontan procedure. This may be due to volume loading and disruption of the normal strain patterns by the intracardiac baffle respectively, similar to the total heart volume findings.

Regardless of the stage of surgical reconstruction or ventricular morphology, 31/33 of single ventricles in that same study twisted counterclockwise in one region, clockwise in another and met at a "transition zone" of no twist. By comparison, the normal human left ventricle twists uniformly in short axis. This "transition zone" had the highest strains of all regions. In the Fontan group, it was demonstrated that the inferior walls moved paradoxically in early systole.

CONCLUSION

It is clear from both a clinical and research standpoint that the advent of CMR has benefited the surgical and medical management of the single ventricle patient. The CMR imager must be familiar with the basic protocol to image these patients along with the wide variety of anatomy, physiology, function and surgical reconstructive techniques which are found in these patients to successfully assess and contribute to these patients overall care. With the continuing advances in CMR, the next 25 years holds even greater promise of progress in the non-invasive assessment of these patients than the past 25.

REFERENCES

1. Fontan F, Baudet E. Surgical repair of tricuspid atresia. Thorax 1971;26:240–248.
2. Norwood WI, Lang P, Hansen D. Physiologic repair of aortic atresia-hypoplastic left heart syndrome. N Engl J Med 1983;308:23–26.
3. Fogel MA, Ramaciotti C, Hubbard AM, Weinberg PW. Magnetic resonance and echocardiographic imaging of pulmonary artery size throughout stages of Fontan reconstruction. Circulation. 1994;90(6):2927–2936.
4. Ro PR, Rychik J, Cohen MS, et al. Diagnostic assessment before fontan operation in patients with bidirectional cavopulmonary anastomosis. are noninvasive methods sufficient? J Am Coll Cardiol 2004;44:184–187.
5. Sano S, Ishino K, Kawada M, et al. Right ventricle-pulmonary artery shunt in first-stage palliation of hypoplastic left heart syndrome. J Thoracic Cardiovasc Surg 2003;126:504–10.
6. Fogel MA, Weinberg PM, Chin AJ, Fellows KE, Hoffman EA. Late ventricular geometry and performance changes of functional single ventricle throughout staged Fontan reconstruction assessed by magnetic resonance imaging. J Am Coll Cardiol 1996;28:212–221.
7. Harris MA, Ghods S, Weinberg PM, Fogel MA. Magnetic resonance delayed enhancement for detection of fibrous tissue in postoperative pediatric patients with various forms of congenital heart disease. J Cardiovasc Mag Reson 2005;7:157.
8. Fogel MA, Weinberg PM, Hoydu A, et al. The nature of flow in the systemic venous pathway in Fontan patients utilizing magnetic resonance blood tagging. J Thorac Cardiovasc Surg 1997;114:1032–1041.
9. Penny DJ, Redington AN. Doppler echocardiographic evaluation of pulmonary blood flow after the Fontan operation: the role of the lungs. British Heart J 1991;66:372–374.
10. Miura T, Matsuda H, Nakano S, et al. Assessment of pulmonary blood flow after total cavopulmonary shunt operation and the modified Fontan procedure for univentricular heart. J Cardio 1998;18:837–844.
11. DiSessa TG, Child JS, Perloff JK, Wu L, Williams RG, Laks H, Friedman WF. Systemic venous and pulmonary arterial flow patterns after Fontan's procedure for tricuspid atresia or single ventricle. Circulation 1984;70:898–902.
12. Frommelt PC, Snider AR, Meliones JN, et al. Doppler assessment of pulmonary artery flow patterns and ventricular function after the Fontan operation. Am J Cardiol 1991;68:1211–1215.
13. Zelicourt DA, Pekkan K, Wills L, Kanter K, Forbess J, Sharma S, Fogel M, Yoganathan A. In vitro flow analysis of a patient-specific intraatrial total cavopulmonary connection. Ann Thorac Surg 2005;79:2094–2102.
14. Fogel MA, Weinberg PM, Rychik J, Hubbard A, Jacobs M, Spray TL, Haselgrove J. Caval contribution to flow in the branch pulmonary arteries of Fontan patients using a novel application of magnetic resonance presaturation pulse. Circulation 1999;99:1215–1221.
15. Hoffman EA, Ritman EL. Invariant total heart volume in the intact thorax. Am J Physiol 1985;249:H883–H890.
16. Hoffman EA, Rumberger J, Dougherty L. A geometric view of cardiac "efficiency." J Am Coll Cardiol 1989;13:86A.
17. Fogel MA, Weinberg PW, Fellows KE, et al. Magnetic resonance imaging of constant total heart volume and center of mass in patients with functional single ventricle before and after staged Fontan procedure. Am J Cardiol 1993;72:1435–1443.
18. Fogel MA, Gupta KB, Weinberg PW, Hoffman EA. Regional wall motion and strain analysis across stages of Fontan reconstruction by magnetic resonance tagging. Am J of Physiol 1995;38:H1132–H1152.