

CONGENITAL HEART DISEASE

Aortic Arch Anomalies

Paul M. Weinberg, MD

The Cardiac Center, The Children's Hospital of Philadelphia, Philadelphia, Pennsylvania, USA

ABSTRACT

Magnetic resonance imaging has become the gold standard for imaging the aortic arch with the ability to demonstrate not only the arterial branching pattern, but also the relationship of aorta and its branches to the trachea and bronchi. Examples of four major aortic arch types—left aortic arch, right aortic arch, double aortic arch and persistent fifth aortic—with most of their variations are demonstrated.

INTRODUCTION

Anomalies of the aortic arch were among the first congenital cardiovascular defects to be examined using clinical magnetic resonance imaging. While the clinical recognition of arch anomalies by plain chest radiograph and barium esophagography goes back decades, the precision of magnetic resonance imaging and computed tomography has virtually supplanted all other imaging techniques when surgical decision making requires an accurate anatomical diagnosis (1–7).

DEFINITIONS

In order to describe the various arch anomalies, some basic definitions are required.

Arch sidedness

An aortic arch is a vessel, whether patent or atretic, that connects the ascending and descending aorta. There are three basic types of aortic arch from the standpoint of the sidedness: left, right and double. Arch sidedness refers to the side of the trachea that the aortic arch passes as it crosses a mainstem bronchus.

This means that an ascending aorta that swings far to the right of the trachea before traveling back to the left and crossing the left mainstem bronchus is a left aortic arch. This may be difficult to appreciate with projection imaging such as angiography but is easily recognized on magnetic resonance imaging. Right aortic arches cross over the right mainstem bronchus. Double aortic arches consist of two aortic arches, one crossing the right and the other crossing the left mainstem bronchus.

Vascular ring

A vascular ring is an anomaly in which the trachea and esophagus (or its atretic remnant) are completely surrounded by vessels. These may include aortic arch or arches, arch vessels, pulmonary artery branch or branches (any of which may be patent or atretic), and ductus arteriosus or ligamentum arteriosum (Henceforth, ductus will be understood to mean ductus arteriosus and ligamentum, ligamentum arteriosum). Vascular rings may be sufficiently tight to cause clinical symptoms or may be loose enough to be asymptomatic. Symptoms are typically respiratory in nature at ages less than two years and relate to dysphagia in older children and adults although less frequently respiratory symptoms have been noted in older children and adults (8).

Since not all components of a vascular ring may be patent, and only vessels carrying blood may be visualized by magnetic resonance imaging (or any other currently available imaging modality other than direct inspection) there are three “Ds” for diagnosing vascular rings when the trachea and esophagus are not surrounded by patent vessels:

(Ductus) Dimple opposite the side of the arch

Diverticulum opposite the side of the arch

(Proximal) Descending Aorta opposite the side of the arch

Each of these will be described in more detail under the specific arch anomalies. The importance of these is that even in the

Received 2 August 2005; accepted 19 December 2005.
Keywords: Aortic Arch, Vascular Ring, Arch Anomaly, Right Aortic Arch, Double Aortic Arch, Persistent Fifth Arch.
Correspondence to:
Paul Weinberg
The Cardiac Center
The Children's Hospital of Philadelphia
Philadelphia, PA, 19104
fax: 215-590-5825
email: weinberg@email.chop.edu

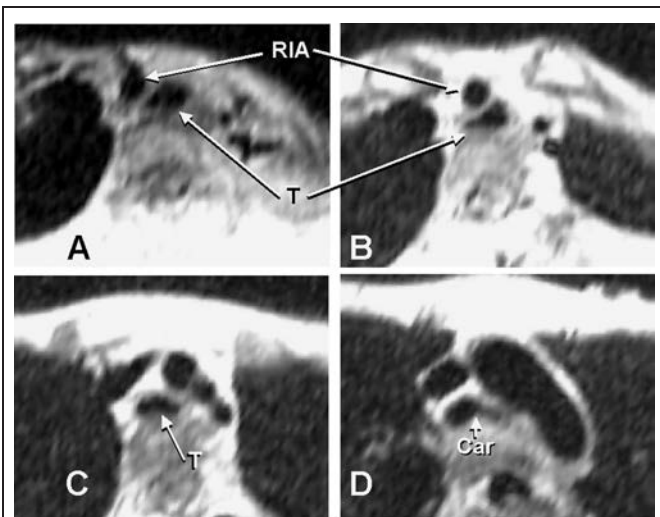


Figure 1. Innominate artery compression of trachea. Axial black blood images showing distortion of the trachea (T) from its nearly round shape in Fig. 1A to a more triangular shape in Fig. 1B at the point where the right innominate artery (RIA) crosses it. The trachea is also abnormally flattened in Fig. 1C, and some distortion of the left bronchus is noted in Fig. 1D at the level of the carina (Car).

absence of visualization of vessels on all sides of the trachea and esophagus, one can make the diagnosis of vascular ring with certainty.

Non-ring tracheo-bronchial or esophageal compression by arch or arch vessels

Sometimes the trachea or bronchi may be partially compressed by the great arteries without a complete ring. Cases of innominate artery compression of the trachea (Fig. 1), anomalous origin of the left pulmonary artery from the right pulmonary artery, so-called pulmonary artery “sling (Fig. 2),” and the aorta wrapping part way around the trachea (Fig. 3) are examples of this. In cases where the aortic arch is oriented in a sagittal plane as is frequently the case with right aortic arches but can also occur in left arches with the ascending aorta in an unusual leftward position, the left mainstem bronchus may be compressed by the ascending and descending aorta plus the interposed right pulmonary artery (Fig. 4).

PARTICULAR ADVANTAGES OF MRI FOR ARCH ANOMALIES

Magnetic resonance imaging is clearly one of many imaging modalities by which arch sidedness and branching pattern may be discerned. However, the importance of simultaneous visualization of the trachea and bronchi along with vessels degrades the potential contributions of angiography and ultrasound examinations. Recognition of airway compression by vascular structures is a valuable adjunct to determination of arch anatomy. Furthermore, even in those cases where arch sidedness alone is the goal

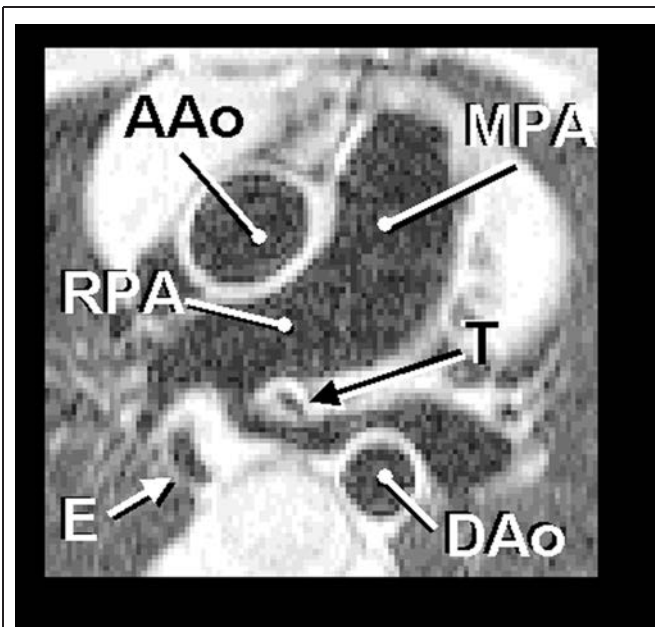


Figure 2. Anomalous origin of the left pulmonary artery from the right, so-called pulmonary artery sling. The left pulmonary artery arises from the right (RPA) instead of from the main pulmonary artery (MPA) and passes between T and esophagus (E). AAO = ascending aorta; DAAo = descending aorta. Reproduced with permission (14).

of imaging, such as in planning for surgical repair of esophageal atresia, artifacts introduced by the lungs and airway negatively affect the ability to accurately assess the relationship of aortic arch to trachea. Therefore, branching pattern is often used as a surrogate for arch-sidedness. As a general rule the first arch vessel (typically carotid artery or innominate artery) travels to the side **opposite** the side of the aortic arch. However, there are exceptions to this rule: 1) Rarely a retroesophageal innominate artery arises as the last vessel from the arch rather than the first. Thus, the first arch vessel, a carotid artery, is ipsilateral to the arch. 2) More commonly, both carotid arteries may arise adjacent to each other so that one cannot distinguish which is first.

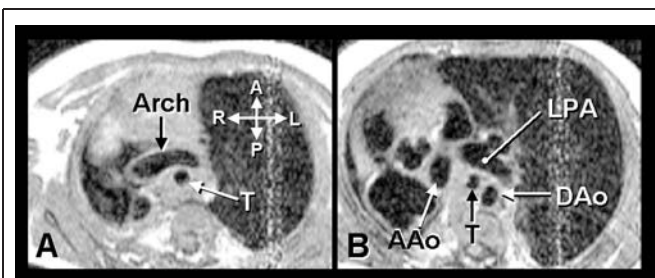


Figure 3. Tracheal compression by aortic arch without ring. Case of marked dextrocardia with extreme rightward displacement of AAO. Note coronal orientation of aortic arch (Arch) in Fig. 3A and narrowing of T in Fig. 3B. LPA = left pulmonary artery. Reproduced with permission (15).

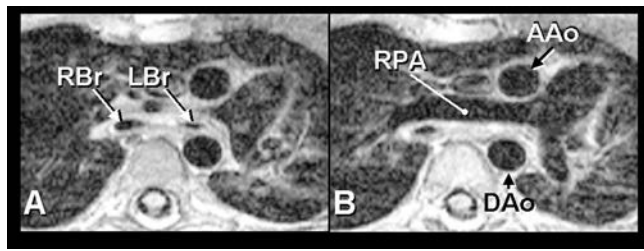


Figure 4. Compression of left mainstem bronchus by ascending and descending aorta in sagittally oriented aortic arch. Normal AAo is to the right of the midline. Here it is to the left, directly anterior to the DAo. Smaller left mainstem bronchus (LBr) seen in Fig. 4A is totally compressed in Fig. 4B. RBr = right mainstem bronchus; RPA = right pulmonary artery. Reproduced with permission (15).

3) If one can distinguish which is first, right or left arch may be diagnosed incorrectly when, in fact, there is a double aortic arch. In all of these cases significant errors in diagnosis can result from inappropriate application of the branching rule. Another rule that we believe has no exceptions states that a retroesophageal or an isolated subclavian artery is always opposite the side of the aortic arch. While this rule is more reliable than the previously noted one, it is also more difficult to apply. Retroesophageal vessels are difficult to see with ultrasound since they run behind the air-filled trachea. Furthermore the aorta coursing behind the esophagus, as noted on barium swallow, can be mistaken for a retroesophageal subclavian artery.

While barium esophagography and echocardiography can accurately determine arch-sidedness and presence of a vascular ring in the majority of cases, neither modality can reliably delineate the optimal site for division of a ring, particularly in those cases with atretic or hypoplastic segments. Therefore, the surgeon is required to do more extensive dissection in order to find the best location for division. It is also noteworthy that errors in determining arch sidedness from barium swallow or echocardiography are not that rare, and their occurrence may result in bilateral thoracotomies. In the current era of minimally invasive surgery, precise definition of arch anatomy, such as that provided by magnetic resonance imaging noninvasively, is superior to the aforementioned techniques as well as to the more invasive angiographic methods.

MR TECHNIQUES FOR EVALUATION OF ARCH ANOMALIES

The protocol for imaging the aortic arch and related structures is designed to accomplish the following: 1) rapid identification of the basic arch anatomy so that necessary surgery can be carried out, even if the patient becomes unstable from a respiratory standpoint before completion of a comprehensive study; 2) determination of tracheo-bronchial compression and its relationship to vascular structures; and in the case of vascular

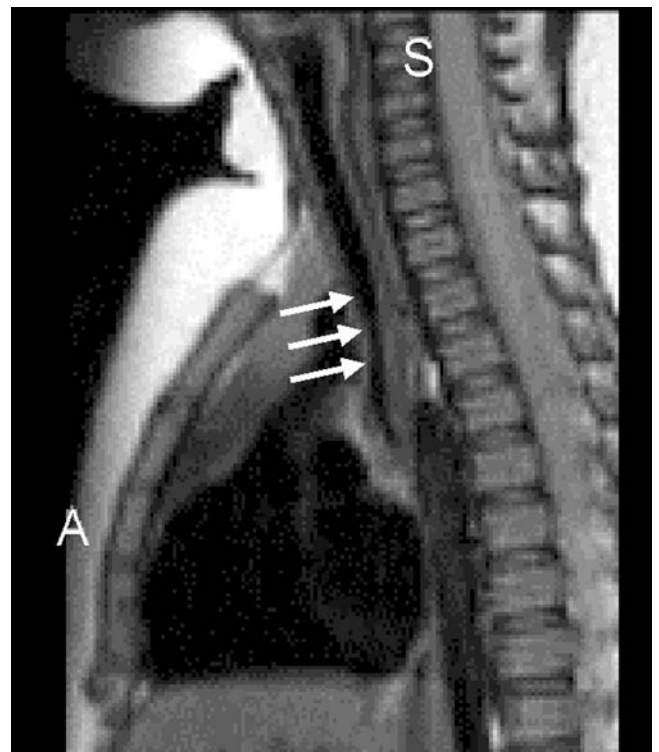


Figure 5. Sagittal image demonstrating extent of tracheal narrowing. Arrows show tracheal narrowing.

rings 3) optimal imaging of the aortic arch to determine the ideal site for division.

2D imaging

The study begins with simple transverse/axial imaging from a level in the neck just below the larynx, down to the level of the diaphragm. Trachea and esophagus are identified, and any area of narrowing or distortion of the nearly circular trachea is noted. Each arch vessel is followed from its respective termination down to the level of the aortic arch. If time permits, simple coronal imaging affords rapid cross-sectional imaging of the aortic arch(es) on either side of the trachea, which is helpful in deciding which arch is larger in the case of double aortic arch. This view is also useful in recognizing a diverticulum (discussed below) in vessels running more vertically than horizontally. Also, if time permits, a series of simple sagittal images is particularly useful for assessing the linear extent and degree of tracheal narrowing (Fig. 5).

3D imaging

After 2D imaging in one or more standard planes, gadolinium injection is performed to provide a 3D shaded surface display of the aorta. In the case of a vascular ring, this further facilitates decisions about where best to divide it. The other application of 3D imaging is to allow curved cuts through the aorta for cases where tortuosity obscures areas of narrowing. By essentially

re-slicing the aorta along its major axis, areas of stenosis or hypoplasia become more evident.

Flow assessment

Finally, in cases of double aortic arch where there is a question of which arch to divide, velocity mapping in the two arches will show which carries the lesser blood flow and therefore would be the better one to divide.

NORMAL LEFT AORTIC ARCH

The normal left aortic arch (Fig. 6) is characterized by a rightward ascending aorta that courses leftward and posterior crossing over the left mainstem bronchus and to the left of the trachea with the descending aorta to the left of the spine. The first arch vessel is a right innominate artery that gives rise to the right subclavian and right carotid arteries. The right subclavian in turn gives rise to the right vertebral artery. The second vessel is a left carotid artery, and the third is a left subclavian artery. In 10% of normal people, the left vertebral artery arises directly from the aortic arch as the third vessel just anterior to the left subclavian, which would then be fourth. If one only looks at the origins of the arch vessels, this variation could be confused with anomalous right subclavian (see below); however, the marked size discrepancy (vertebral smaller than subclavian) helps distinguish these two conditions.

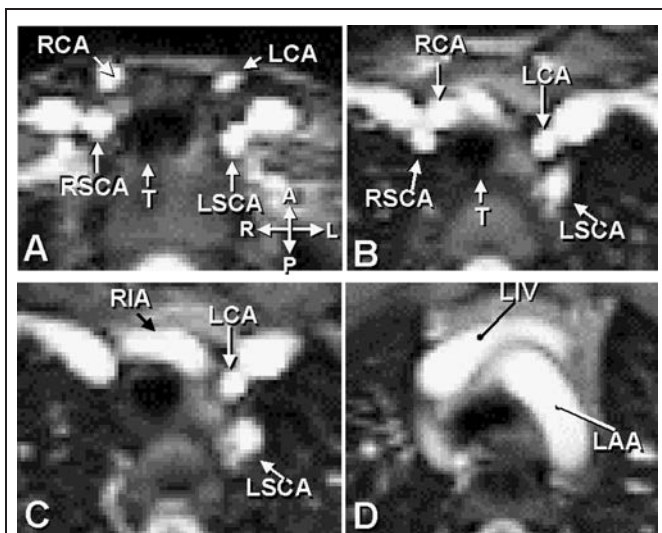


Figure 6. Normal left aortic arch. Axial TruFISP images of normal aortic arch for comparison with subsequent images. In this and subsequent axial images, the order of display is superior to inferior. All axial images are oriented as shown by the crossed double-headed arrows. A = anterior, L = left, P = Posterior, R = Right. LAA = left aortic arch, LCA = left carotid artery, LIV = left innominate vein, LSCA = left subclavian artery, RCA = right carotid artery, RIA = right innominate artery, RSCA = right subclavian artery.

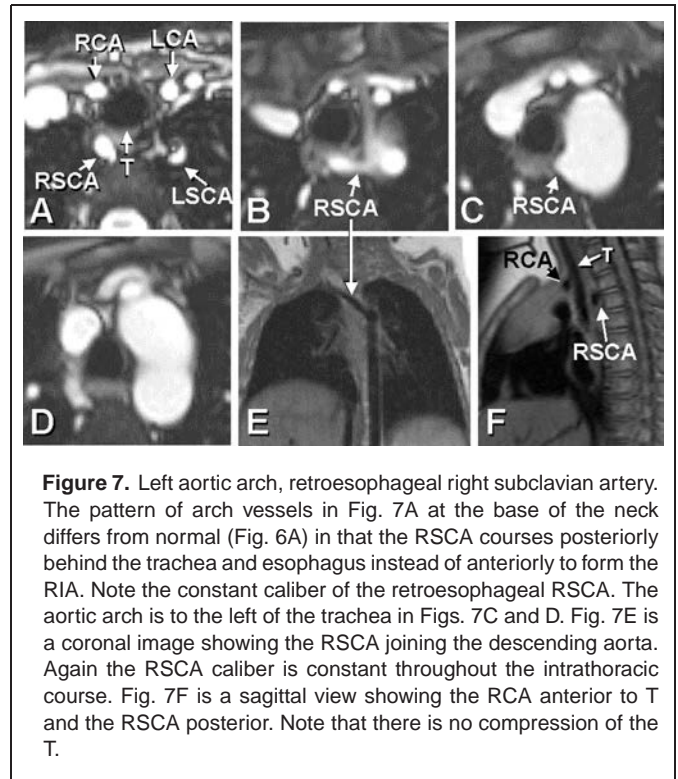


Figure 7. Left aortic arch, retroesophageal right subclavian artery. The pattern of arch vessels in Fig. 7A at the base of the neck differs from normal (Fig. 6A) in that the RSCA courses posteriorly behind the trachea and esophagus instead of anteriorly to form the RIA. Note the constant caliber of the retroesophageal RSCA. The aortic arch is to the left of the trachea in Figs. 7C and D. Fig. 7E is a coronal image showing the RSCA joining the descending aorta. Again the RSCA caliber is constant throughout the intrathoracic course. Fig. 7F is a sagittal view showing the RCA anterior to T and the RSCA posterior. Note that there is no compression of the T.

LEFT ARCH ANOMALIES

Retroesophageal right subclavian artery (Fig. 7)

The most common aortic arch anomaly is left aortic arch with anomalous right subclavian artery. The sequence of arch vessels is right carotid artery, left carotid, left subclavian, with the last vessel being a retroesophageal right subclavian artery. This does not form a vascular ring since the trachea and esophagus are only bordered on three sides by vascular structures – nothing passes to the right. In the older literature, this anomaly was referred to as dysphagia lusoria: dysphagia due to a “trick” of nature. This symptom is rare in children but is seen in a small number of adults.

Left arch, right descending aorta (Fig. 8)

This is a rare arch anomaly (9) in which the aorta passes to the left of the trachea, swings immediately to the right behind the trachea and esophagus, and then turns inferiorly to become the descending aorta. A right ductus or ligamentum connects the rightward descending aorta to the right pulmonary artery, thus completing a vascular ring. The branching pattern is usually similar to that seen above with anomalous right subclavian artery although a normal branching pattern with right innominate artery is theoretically possible. The difference from the previously described retroesophageal right subclavian artery is that while the branching sequence is the same, it is the aortic arch itself that is retroesophageal; the right subclavian artery arises from the aorta after it has become right-sided. Therefore the right subclavian

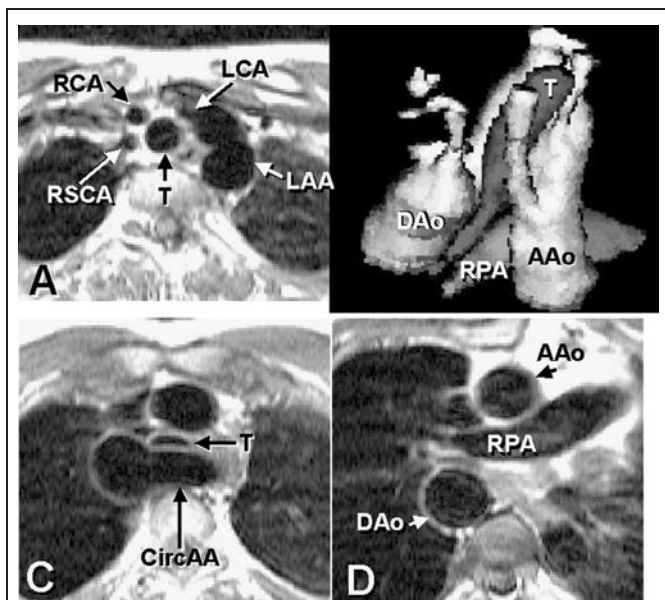


Figure 8. Left aortic arch, right descending aorta. Rare vascular ring. Axial images in Figs. 8A, C, and D, and a shaded surface display in Fig. 8B created from semiautomated reconstruction from standard black-blood spin echo images. The branching sequence is similar to that in Fig. 7, but the aortic arch itself passes retroesophageally – circumflex aortic arch (CircAA). This pattern only occurs when there is a ductus or ligamentum connecting the right descending aorta to the right pulmonary artery. Note the flattening of the T in Fig. 8C. Reproduced with permission (16).

artery is anomalous, i.e., separate origin as the last arch vessel but not itself retroesophageal. This type of arch anomaly in which the aorta loops around the trachea and passes retroesophageally is referred to as a circumflex aortic arch and always forms a vascular ring, even though the ring is usually completed by a ligamentum, which is not visualized by any imaging modality.

RIGHT AORTIC ARCH ANOMALIES

Right aortic arches are a diverse set of anomalies including the second and third most common vascular rings. Because the aorta usually arises to the right of the midline (irrespective of arch sidedness) and, with one exception, right aortic arches begin descending on the right, there is a chance that the right mainstem bronchus will be compressed between the sagittally oriented ascending and descending aorta as described above. In situs solitus (normal arrangement of asymmetrical body organs and atria) the descending aorta is left sided at the diaphragm irrespective of arch sidedness. Thus with right aortic arches the aorta must go from being right-sided at the level of the bronchi to left-sided at the diaphragm. In most cases this is a gradual diagonal passage with no perceptible indentation on the esophagus. However, in one situation – right aortic arch with left descending aorta – similar to left arch right descending above, the crossing is abrupt and associated with a ring.

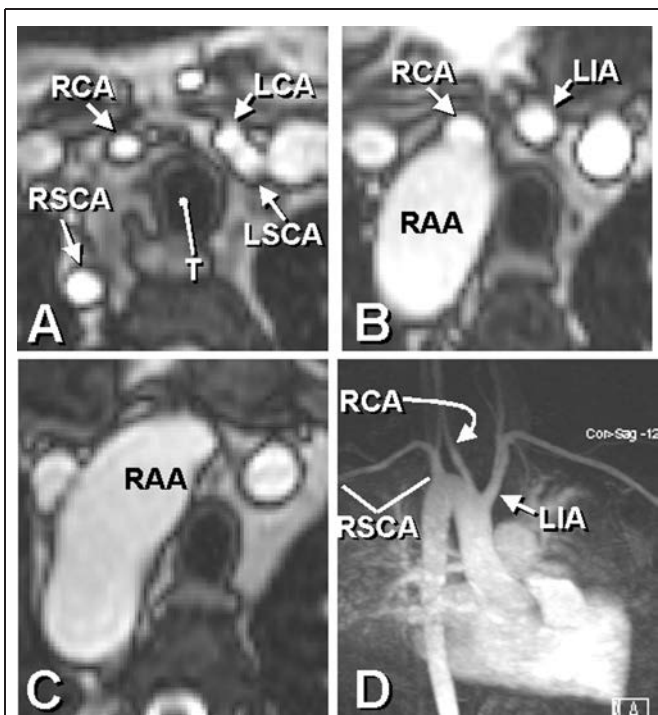


Figure 9. Mirror image right aortic arch. Axial static TruFISP images in Figs. 9A, B, C, and gadolinium enhanced MR angiography in Fig. 9D show the branching pattern of mirror image right aortic arch (RAA). The fact that the ascending aorta is usually to the right irrespective of arch sidedness, results in a more acute bend in the aortic arch seen best in Fig. 9D. Note that mirror image branching includes a left innominate artery (LIA) as the first branch.

Mirror image right aortic arch (Fig. 9)

Mirror image right aortic arch is the mirror image of the normal left aortic arch. That means the branching pattern consists of a left innominate artery as the first branch, followed by right carotid, then right subclavian artery. The descending aorta begins on the right. There are several variations on this theme with regard to ductus/ligamentum location. A true mirror image includes a right ductus passing between the aortic arch or proximal descending aorta and the right pulmonary artery. This is the only variation possible in the absence of a major intracardiac abnormality. A left ductus with a right ductus can occur with or without heart disease. A left ductus alone or congenital absence of the ductus can only occur in the presence of a major intracardiac anomaly in which right ventricular blood can reach the aorta without traversing the main pulmonary artery, such as by way of a large ventricular septal defect. This is because a left ductus with mirror image right aortic arch arises from the base of the left innominate artery. If the only egress of blood from the fetal right ventricle were via the pulmonary artery and left ductus, the majority of the cardiac output would take a very tortuous path before reaching the aorta. Furthermore, one would expect to see marked dilatation of the innominate artery because of the high percentage of right ventricular contribution to cardiac output. In reality, this is not seen. Obviously absence

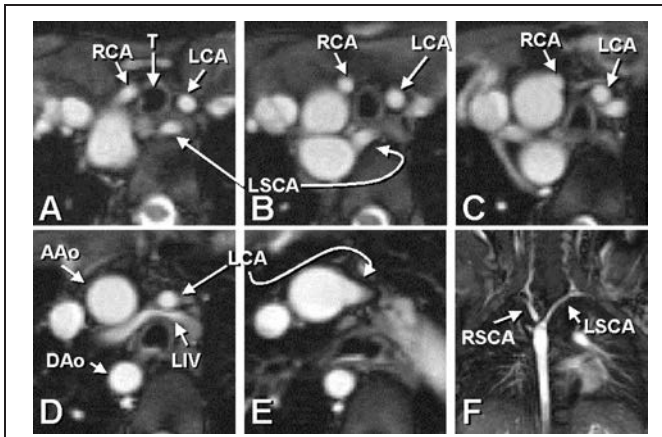


Figure 10. Right aortic arch with retroesophageal left subclavian artery (non-ring). Axial TruFISP images in Figs. 10A–E, and coronal image in Fig. 10F. This anomaly is the mirror image of the anomaly seen in Fig. 7 above. Note the posterior course of the LSCA in Figs. 10A&B. There is frequently a low (i.e., more proximal) take-off of the first arch vessel, the left carotid artery, seen here in the most inferior slice, Fig. 10E. Of particular importance is the constant caliber of the LSCA throughout its intrathoracic course seen best in Fig. 10F. There is an incidental finding of a retroaortic left innominate vein (LIV) seen in Fig. 10D).

of the ductus requires major intracardiac shunting for the same reason.

Right aortic arch with retroesophageal left subclavian artery (non-ring) (Figs. 10, 11)

This anomaly is the mirror image of left aortic arch with retroesophageal right subclavian artery. The branching sequence

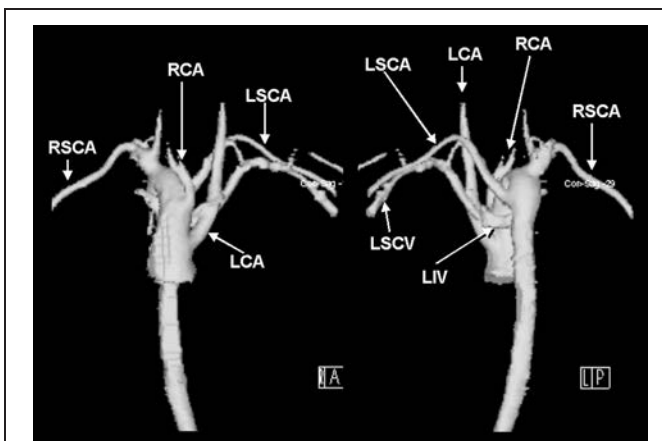


Figure 11. Right aortic arch with retroesophageal subclavian artery. 3D shaded surface display of from gadolinium enhanced MR angiography. (Same case as in Fig. 10). The left hand image (A) is an anterior view and the right (P) a posterior view. Note the low take-off of the left carotid artery. The unusual retroaortic LIV drains the left subclavian vein, which, on casual inspection could be mistaken for the left subclavian artery, giving the false impression of an innominate artery.

is left carotid, right carotid, right subclavian and anomalous left subclavian arteries. If there is no major intracardiac anomaly, there must be a right ductus or ligamentum. With intracardiac shunt there can be congenital absence of the ductus. From a diagnostic standpoint, the caliber of the anomalous left subclavian artery is relatively constant from its origin in the proximal descending aorta for most of its intrathoracic course. There is no vascular ring since there is no vessel passing to the left of the trachea and esophagus. An indentation on the barium filled esophagus will be noted.

Right aortic arch with diverticulum of Kommerell (Fig. 12)

The branching pattern for this anomaly is virtually identical to the retroesophageal left subclavian artery described above with one important difference. Instead of the subclavian artery having a constant caliber, the retroesophageal portion is notably larger than the remainder of the vessel. The larger caliber proximal portion is referred to as an aortic diverticulum. There is an abrupt tapering of the vessel best appreciated on coronal imaging. This pattern is associated with the presence of a left ductus or ligamentum connecting left pulmonary artery to the diverticulum forming a vascular ring. This is the second most common vascular ring after double aortic arch. The so-called diverticulum is due to fetal ductal flow to the descending aorta by way of the proximal subclavian artery. While the ligamentum is not visible with any imaging modality, the aortic diverticulum assures the

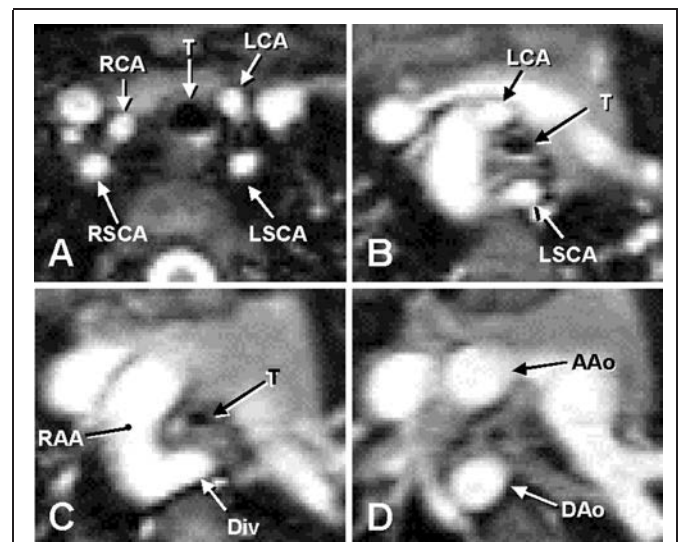


Figure 12. Right aortic arch with retroesophageal diverticulum of Kommerell. Axial TruFISP images show a left subclavian artery with an abnormally posterior orientation and course, similar to Fig. 10 above. However the marked and abrupt change in caliber, best seen from Fig. 12B to 12C is characteristic of a diverticulum of Kommerell (Div) which only occurs with a vascular ring, usually from a ductus arteriosus joining the aberrant subclavian artery. This appearance can also be seen with some forms of double aortic arch. See Fig. 18 below. Note the marked tracheal narrowing from Fig. 12A to 12C.

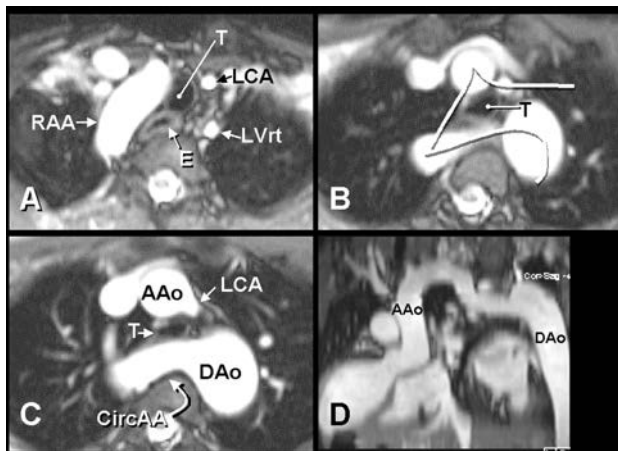


Figure 13. Right aortic arch with left descending aorta. Axial Tru-FISP images in Figs. 13A–C. RAA that passes behind the trachea and esophagus seen in Figs. 13B&C, so-called circumflex aortic arch (CircAA). This anomaly is much more common than its mirror image shown in Fig. 8 above. The tortuosity of the aorta makes it difficult to evaluate in any single plane. Fig. 13D is the result of a “curved cut” along the path described by the line shown in Fig. 13B. The aorta is effectively uncurled for better appreciation of its caliber throughout. As with the case shown in Fig. 8, the presence of a CircAA assures the presence of a vascular ring. LVrt = left vertebral artery, which joins the LSCA more inferiorly.

presence of a vascular ring completed by a ligamentum. In some cases an atretic left aortic arch may also be present (see below).

Right aortic arch left descending aorta (Figs. 13, 14)

This anomaly, also known as circumflex aortic arch, is the third most common form of vascular ring. There are two branching patterns associated with this anomaly. One has an anomalous left subclavian artery that is not retroesophageal – essentially the mirror image of the rare left aortic arch with right descending aorta described above. The other has a mirror image right aortic arch branching pattern—left innominate, right carotid, right subclavian arteries—with the aortic arch itself passing retroesophageally to the left of the spine where it is joined by the left ductus or ligamentum. Both of these patterns are indistinguishable from double aortic arch with atretic left arch described below.

Right aortic arch with retroesophageal left ductus or ligamentum (Fig. 15)

This is a rare form of vascular ring (10) with a mirror image right aortic arch branching pattern, but with a left ductus or ligamentum arising from the right descending aorta and passing behind the esophagus to join the left pulmonary artery. The evidence for this anomaly is a small ductus dimple pointing to the left from a right descending aorta. Some cases of double aortic arch with atretic left arch may have a similar pattern although most double arches have a left descending aorta.

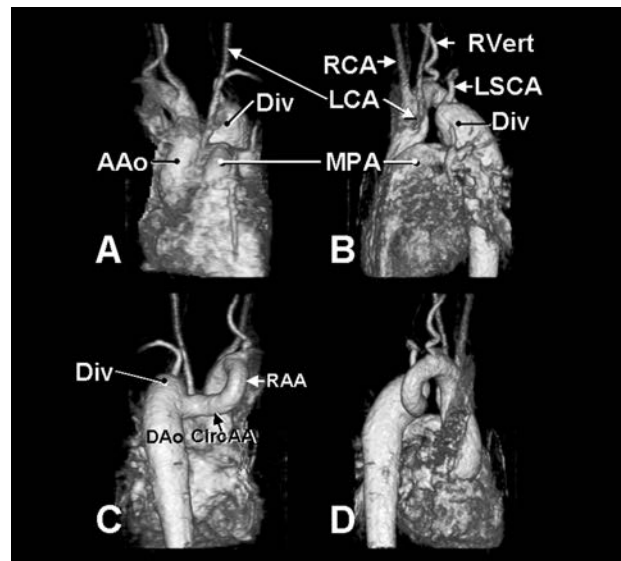


Figure 14. Right aortic arch with left descending aorta. 3D shaded surface display of same case shown in Fig. 13. The marked tortuosity of the aorta is again appreciated. Fig. 14A is an anterior view, 14B left lateral, 14C posterior, and 14D right lateral. In this case a diverticulum (Div) receives both the left subclavian artery, which is aberrant but not retroesophageal, and the ligamentum arteriosum.

Right aortic arch with retroesophageal left innominate artery (non-ring) (Fig. 16)

This is a very rare arch anomaly (11) in which the first arch vessel is a right carotid artery in “violation” of the usual rule

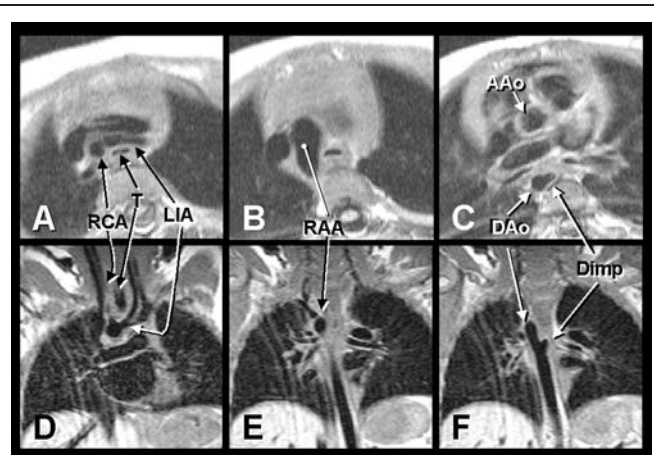


Figure 15. Right aortic arch with left ductus or ligamentum. Axial (Figs. 15A–C) and coronal (Figs. 15D–F) black-blood images demonstrate a rare vascular ring. The branching pattern appears to be a mirror image right aortic arch, but the ductus dimple (Dimp) seen heading leftward from the descending aorta (Figs. 15C and F) indicates a left-sided ligamentum, which completes a vascular ring with a right aortic arch. Of note is the fact that a left ductus or ligamentum from a left innominate artery would not create a ring, but this vessel courses posterior to the trachea and esophagus; whereas a ligamentum from a left innominate artery does not.

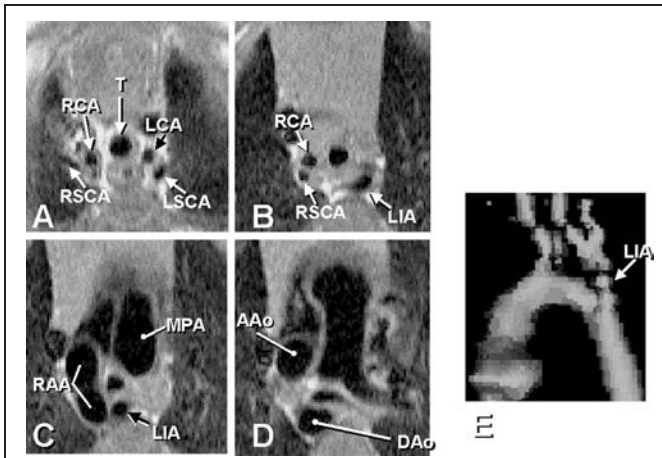


Figure 16. Right aortic arch with retroesophageal left innominate artery (LIA). Axial black-blood images and three-dimensional shaded surface display reconstructed from this study shows a rare anomaly: the LSCA and LCA form a single vessel which passes posterior to the esophagus and trachea. Just as in retroesophageal subclavian artery, unless there is a diverticulum indicating a ligamentum, there is no vascular ring.

that the first arch vessel contains a carotid artery *opposite* the side of the arch. The second branch is the right subclavian, and the last is a vessel that gives rise to both the left carotid and left subclavian arteries – designated innominate artery. The anomaly

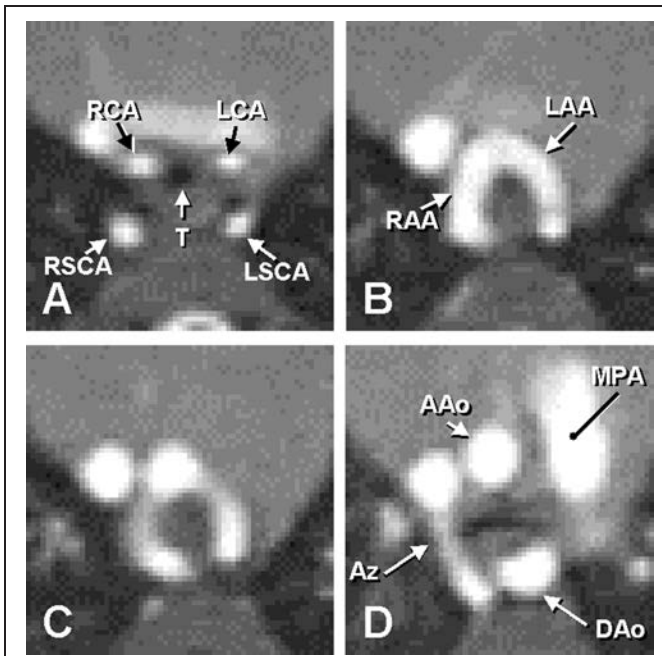


Figure 17. Double aortic arch, dominant right arch, both arches patent. Axial TruFISP images show symmetrical arch vessels in Fig. 17A joining both right and left aortic arches in Fig. 17B. While no single plane shows the complete ring it is evident that both arches are complete. The most common pattern, right arch larger than left, is shown here in Fig. 17B. The azygos vein (Az) is parallel to the right arch but should not be confused with it.

ous innominate, while producing a relatively large indentation on the barium-filled esophagus, does not create a vascular ring as there is no left-sided vessel completing the ring.

DOUBLE AORTIC ARCH

Double aortic arch is a persistence of both the left and right embryonic fourth arches and left and right dorsal aortas. Typically the descending aorta is on the left although a midline or right-sided position of the proximal descending aorta are possible. In most but not all cases, the right arch is larger than the left (dominant right arch), but equal sized arches and even dominant left arch are known.

If there is no associated major intracardiac anomaly, as is usually the case, there must be a ductus. Typically it is left-sided. Right-sided ductus can occur. Bilateral ductus is theoretically possible, but its occurrence is extremely rare. The importance of ductus or ligamentum location is that it may need to be divided at the same time as division of one of the arches for relief of the vascular ring. If it is not, the ductus or ligamentum can still complete a ring, even though the arch is successfully divided.

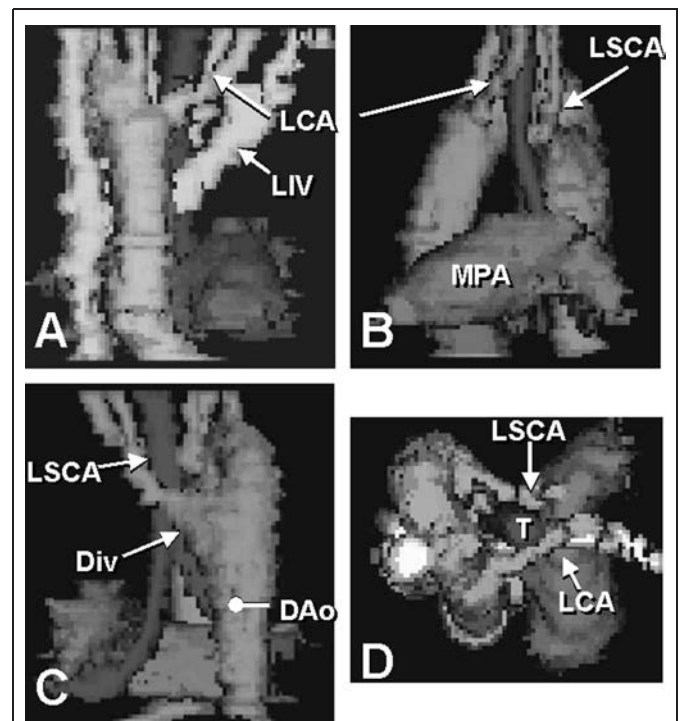


Figure 18. Double aortic arch, atretic left arch between carotid and subclavian arteries. Shaded surface displays constructed from standard spin-echo images. Fig. 18A is an anterior view, 18B, left lateral, 18C posterior, and 18D cranial view. The first arch vessel seen in Figs. 18A&B is the LCA and the last, the LSCA. Fig. 18C shows a diverticulum giving rise to the aberrant LSCA similar to that seen in Fig. 12 above. An atretic left aortic arch joining the LCA and LSCA was found at surgery. These two lesions may be indistinguishable by any imaging modality. The tethered appearance of the two vessels in 18D is suggestive of an atretic arch, but both diagnoses should always be considered with this pattern.

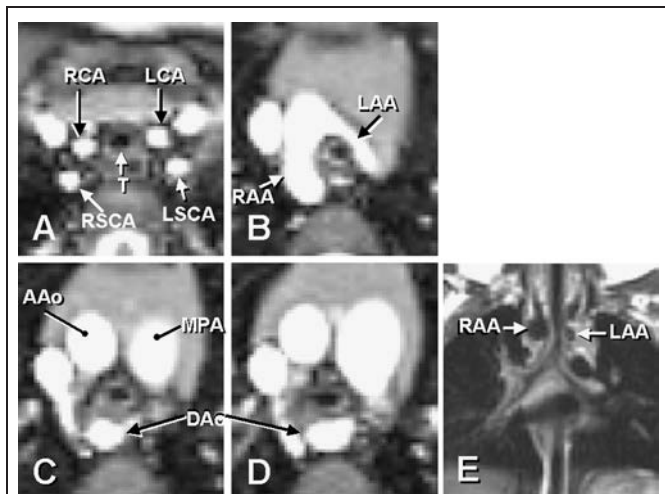


Figure 19. Double aortic arch, atretic left arch distal to left subclavian artery. Axial TruFISP images (Figs. 19A–D) and black-blood coronal image (Fig. 19E) show the more common double aortic arch with atretic left arch. While there is no connection between the LAA in Fig. 19B and the DAo, the small diverticulum from the DAo in Fig. 19C assures that there is a complete ring. Fig. 19E shows the markedly larger RAA.

It is usually relatively easy to determine which of the two arches is smaller and therefore which should be divided in the symptomatic patient. However, in cases where the caliber of the two arches appear similar, one can measure blood flow in the two distal arches using phase encoded velocity mapping. The arch with lesser flow would be the ideal one to divide.

Dominant right arch

By far the most common double arch is a dominant right aortic arch. This is usually evident on coronal imaging in a plane passing through the trachea where the two arches are seen on either side. Typically, the right arch is superior to the level of the left. Occasionally the arches will be of equal size in this plane, but the more posterior portion of the left arch will show more obvious diminution in caliber or may even disappear (i.e., have atresia).

Both arches are patent in the majority of double aortic arches. On axial imaging, one may not appreciate the complete ring in any single slice (Fig. 17). The right arch is almost always superior to the left. Furthermore, the proximal bifurcation is typically superior to the distal confluence of the two arches. Three-dimensional displays facilitate the viewing of the complete ring in a single image. A left or right posterior oblique view with cranial angulation usually eliminates overlapping of structures to best appreciate the ring and the relative sizes of the arches.

Double aortic arch with atretic left arch can occur in either of two configurations: atretic segment between carotid and subclavian arteries (Fig. 18) or distal to the left subclavian artery (Fig. 19) (12). The former may be indistinguishable from right aortic arch with retroesophageal diverticulum of Kommerell in the unusual case of a right descending aorta. However, both pat-

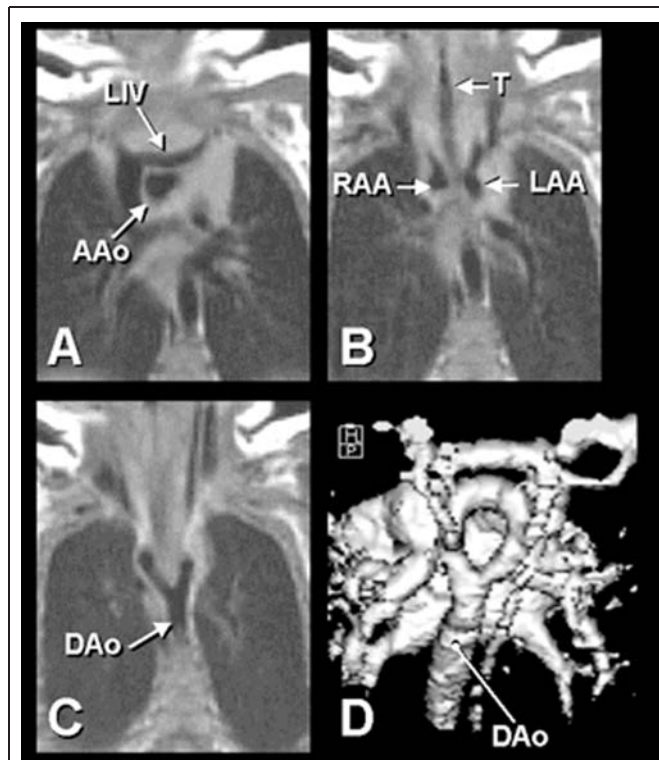


Figure 20. Double aortic arch, equal sized arches. Coronal black-blood images (Figs. 20A–C) and shaded surface display from gadolinium enhanced MR angiography, posterior view with cranial angulation (Fig. 20D). Note the equal sized arches compressing the trachea in Fig. 20B and the continuation of both arches into the DAo in Fig. 20C.

terns may be indistinguishable from the two forms of right aortic arch with left descending aorta. Sometimes there is noticeable tethering of the left carotid or left subclavian artery posteriorly from the atretic arch, but this is not a consistent finding. Therefore, it is best to remind the surgeon who is about to divide a vascular ring thought to be due to right aortic arch with retroesophageal diverticulum or right arch with left descending aorta that there could be an atretic left aortic arch in addition to a left ligamentum.

Equal sized arches (Fig. 20)

These have two well-developed arches that are both patent. Similar to dominant right arch, the right arch is typically superior to the left, sometimes a cervical arch, i.e., superior to the head of the clavicle.

Dominant left arch (Fig. 21)

Double aortic arch with a dominant left arch is uncommon but not rare. This anomaly along with the rare left aortic arch with right descending aorta (noted above) are the two situations where a vascular ring should be divided by way of a right thoracotomy rather than a left. These two anomalies are not usually recognized by barium swallow or echocardiography. Careful attention must

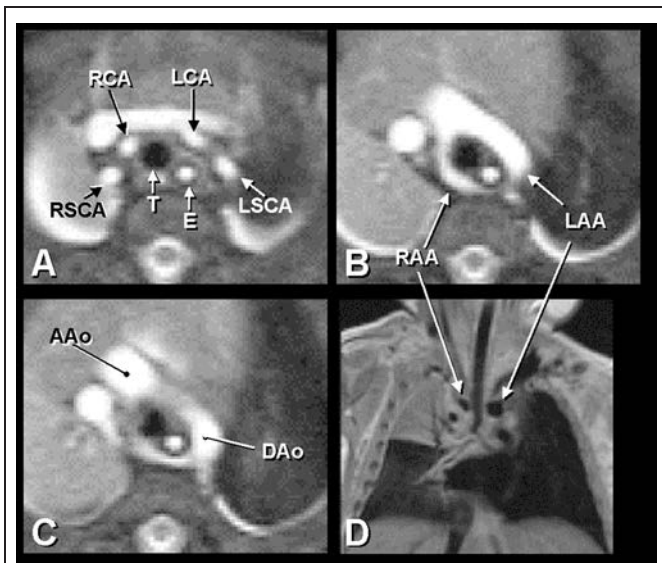


Figure 21. Double aortic arch, dominant left arch. Axial TruFISP images (Figs. 21A-C) and coronal black-blood image (Fig. 21D) demonstrate a relatively uncommon double aortic arch with a larger left arch seen in both axial (Fig. 21B) and coronal (Fig. 21D) view. This appears to be a relatively loose ring with minimal tracheal distortion.

be paid when evaluating a double aortic arch with two patent arches because the caliber may vary in different parts of the arch. As discussed previously, simple axial or transverse imaging for comparison of arch caliber is complicated by the fact that the ring is not seen in any single transverse plane. In addition, as mentioned above, the narrowest portion of the right arch may not occur in the coronal plane where the two arches straddle the trachea. Three-dimensional rendering is especially useful in this situation. Shaded surface displays are particularly helpful

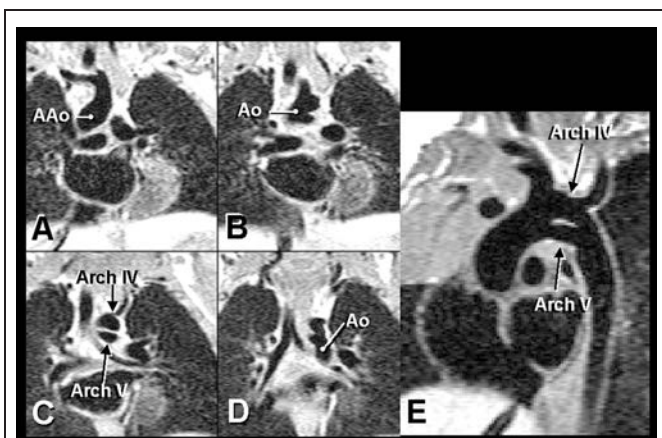


Figure 22. Persistent fifth aortic arch, double-barreled aortic arch. Black-blood coronal (Figs. 22A-D) and off axis sagittal (Fig. 22E) images. Rare incidental anomaly with persistence of embryonic fifth aortic arch. Fig. 22C could be mistaken for a dissection of the aortic arch.

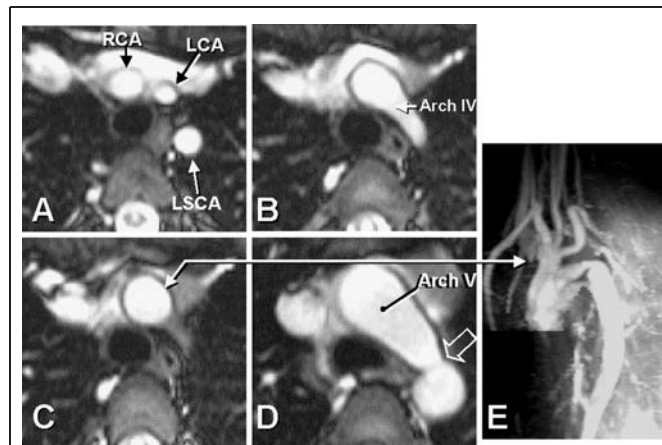


Figure 23. Persistent fifth aortic arch, atretic fourth arch, coarctation of fifth arch. Axial TruFISP images (Figs. 23A-D) and gadolinium enhanced angiography (Fig. 23E). Note relatively normal appearance of arch vessels in Figs. 23A&B. However, the apparent arch (Arch IV), derived from the embryonic fourth aortic arch does not connect to the descending aorta. The distal Arch IV was proven to be atretic at surgery for the coarctation, seen in Fig. 23D (open arrow) and in Fig. 23E. Note the single trunk (double-headed arrow) in Figs. 23C&E from which all arch vessels arise.

in comparing the two arches. In those cases where a discrete coarctation or relatively short hypoplastic segment of the right arch is present, a curved cut along the longitudinal axis of the aorta may be the best way to assess the sizes of the two arches.

PERSISTENT FIFTH AORTIC ARCH

Persistent fifth aortic arch is really two different anomalies in which there are two aortic arches but not a vascular ring. The first – so-called double-barreled aortic arch or “subway” aortic arch – is an asymptomatic curiosity; there are two parallel arches with the brachiocephalic vessels arising from the more superior one (presumably the derivative of the normal embryonic fourth branchial arch [Fig. 22]) (13). Its importance is that it not be confused with a dissecting aneurysm of the aortic arch. The other anomaly consists of atresia of the distal portion of the “normal” aortic arch with patency but coarctation of the distal end of the persistent fifth embryonic arch (Fig. 23). This anomaly is recognized by the apparent origin of all four brachiocephalic vessels from a single stalk—the embryonic fourth arch. The atretic portion is distal to the left subclavian artery. While not visualized by any imaging modality, the unusual appearance of a truly common brachiocephalic trunk identifies this anomaly.

REFERENCES

1. Beekman RP, Hazekamp MG, Sobotka MA, Meijboom EJ, de Roos A, Staalman CR, Beek FJ, Ottenkamp J. A new diagnostic approach to vascular rings and pulmonary slings: the role of MRI. *Magnetic Resonance Imaging* 1998;16:137-145.
2. Burrows PE, MacDonald CE. Magnetic resonance imaging of the pediatric thoracic aorta. *Seminars in Ultrasound, CT & MR* 1993;14:129-144.

3. Eichhorn J, Fink C, Delorme S, Ulmer H. Rings, slings and other vascular abnormalities. Ultrafast computed tomography and magnetic resonance angiography in pediatric cardiology. *Zeitschrift fur Kardiologie* 2004;93: 201–208.
4. Hernandez RJ. Magnetic resonance imaging of mediastinal vessels. *Magnetic Resonance Imaging Clinics of North America* 2002;10:237–251.
5. Julsrud PR, Ehman RL. Magnetic resonance imaging of vascular rings. *Mayo Clinic Proceedings* 1986;61:181–185.
6. Lowe G M, Donaldson J S, Backer C L. Vascular rings: 10-year review of imaging. *Radiographics* 1991;11:637–646.
7. van Son JA, Julsrud PR, Hagler DJ, Sim EK, Puga FJ, Schaff HV, Danielson GK. Imaging strategies for vascular rings. *Annals of Thoracic Surgery* 1994;57:604–610.
8. Parker JM, Cary-Freitas B, Berg BW. Symptomatic vascular rings in adulthood: an uncommon mimic of asthma. *Journal of Asthma* 2000;37:275–280.
9. McLeary MS, Frye LL, Young LW. Magnetic resonance imaging of a left circumflex aortic arch and aberrant right subclavian artery: the other vascular ring. *Pediatric Radiology* 1998;28:263–265.
10. Zachary CH, Myers JL, Egli KD. Vascular ring due to right aortic arch with mirror-image branching and left ligamentum arteriosus: complete preoperative diagnosis by magnetic resonance imaging. *Pediatric Cardiology* 2001;22:71–73.
11. Midiri M, Finazzo M, Pilato M, Lagalla R, De Maria M. Right aortic arch with aberrant left innominate artery: MR imaging findings. *European Radiology* 1999;9:311–315.
12. Schlesinger AE, Krishnamurthy R, Sena LM, Guillerman RP, Chung T, DiBardino DJ, Fraser CD, Jr. Incomplete double aortic arch with atresia of the distal left arch: distinctive imaging appearance. *American Journal of Roentgenology* 2005;184:1634–1639.
13. Yang S-G, Fogel MA, Stephens P Jr, Bellah R, Weinberg PM. Non-invasive imaging of isolated persistent fifth aortic arch. *Pediatric Cardiology* 2003;24:179–181.
14. Weinberg PM. Aortic arch anomalies. In: Allen HA, Gutgesell HP, Clark EB, Driscoll DJ, eds. *Moss and Adams' Heart Disease in Infants, Children, and Adolescents Including the Fetus and Young Adult*. Philadelphia: Lippincott Williams & Wilkins, 2001. p. 732, Fig 34–16.
15. Weinberg PM, Fogel MA. Cardiac MR imaging in congenital heart disease. *Cardiology Clinics*. Elsevier, 1998;16:318–319, Fig 4 B,C; Fig 5 C,D.
16. Weinberg PM, Hubbard AM, Fogel MA. Aortic arch and pulmonary artery anomalies in children. *Seminars in Roentgenology*, Elsevier, 1998;33:264, Fig 1 C,E.